

Technical Note

Arthroscopic Bone Grafting of Deep Acetabular Cysts Using a Curved Delivery Device

Tigran Garabekyan, M.D., Vivek Chadayammuri, B.S., Cecilia Pascual-Garrido, M.D., and Omer Mei-Dan, M.D.

Abstract: Acetabular intraosseous cysts are frequently encountered in patients with dysplasia or femoroacetabular impingement. Small cysts are typically addressed by removing the cyst lining and stimulating healing via microfracture or abrasion chondroplasty. In contrast, larger cysts involving 1-3 cm³ frequently require additional fortification with bone graft material to facilitate osseous ingrowth and cyst healing. Previous arthroscopic reports have described the use of rim trimming to access the extra-articular side of the cyst, with subsequent use of straight metal cannulas for delivery of bone graft material. The downsides of this technique include the requirement for rim trimming, which may be ill advised in patients with normal coverage or dysplasia, as well as the creation of a second breach in the cyst wall, precluding pressurization of the bone graft material. We describe an arthroscopic technique using a curved delivery device allowing for deeper penetration into the cyst cavity through the articular side and greater delivery of bone graft material.

Acetabular intraosseous cysts are frequently encountered in patients with femoroacetabular impingement (FAI) and dysplasia.¹ With few exceptions,^{2,3} most of cysts are considered pathologic and a source of pain warranting treatment at the time of surgery.^{1,4,5} The prevailing approach for smaller cysts (< 1 cm³) entails evacuating the cystic contents, removing the lining, and stimulating osseous healing via abrasion chondroplasty or microfracture.^{4,5} Larger cysts (> 1 cm³) have been addressed exclusively with “outside-in” drilling using open⁴ and arthroscopic techniques,⁵ necessitating the creation of a second, extra-articular, breach into the cyst contents.

To address the aforementioned shortcomings, we present an arthroscopic technique using a curved delivery device allowing for deeper and more precise penetration into the cyst cavity through the articular side and greater delivery of bone graft material.

From Hip Preservation Center, Sports Medicine, Orthopedics Department, University of Colorado (T.G., C.P.G., O.M.-D.); and University of Colorado School of Medicine (V.C.), Aurora, Colorado, U.S.A.

The authors report that they have no conflicts of interest in the authorship and publication of this article.

Received July 19, 2015; accepted October 27, 2015.

Address correspondence to Omer Mei-Dan, M.D., Sports Medicine and Hip Preservation Service, Department of Orthopedics, University of Colorado School of Medicine, 12631 E 17th Av, MailStop B202, Academic Office 1, Room 4602, Aurora, CO 80045, U.S.A. omer.meidan@ucdenver.edu

© 2016 by the Arthroscopy Association of North America

2212-6287/15675/\$36.00

<http://dx.doi.org/10.1016/j.eats.2015.10.012>

Surgical Technique

Preoperative and Intraoperative Evaluation

Preoperative evaluation of the painful hip includes a thorough history, physical examination, and radiographic studies aiming to identify underlying impingement and/or instability characteristics (Fig 1A). Acetabular intraosseous cysts may be identified on contrast and noncontrast MRI and should be evaluated for size, consistency, and location. A computed tomography scan provides greater bony detail to allow for more accurate sizing and localization of the cyst and because of its higher resolution may reveal the intra-articular breach (Fig 1 B-D). In dysplastic patients, these cysts may be assumed to communicate directly with the joint space,¹ even if an intra-articular breach is not clearly visible. Heterogeneous cysts in atypical locations should be evaluated for malignancy by an orthopaedic oncologist. Incidental and benign appearing (non mechanical) cysts in asymptomatic hips are observed with close follow-up.

Hip arthroscopy is carried out in a standard fashion using a previously described technique.⁶ During central compartment evaluation, the area of the suspected intra-articular breach is inspected for change in color or texture, keeping in mind that most of such lesions are visually unimpressive and seemingly innocuous. The area is gently probed with a blunt instrument (Fig 2A) to reveal an unstable cartilage flap or wave delamination, signifying accurate localization of the intra-articular breach. FAI pathology is then addressed with labral repair, femoral osteoplasty, and rim trimming

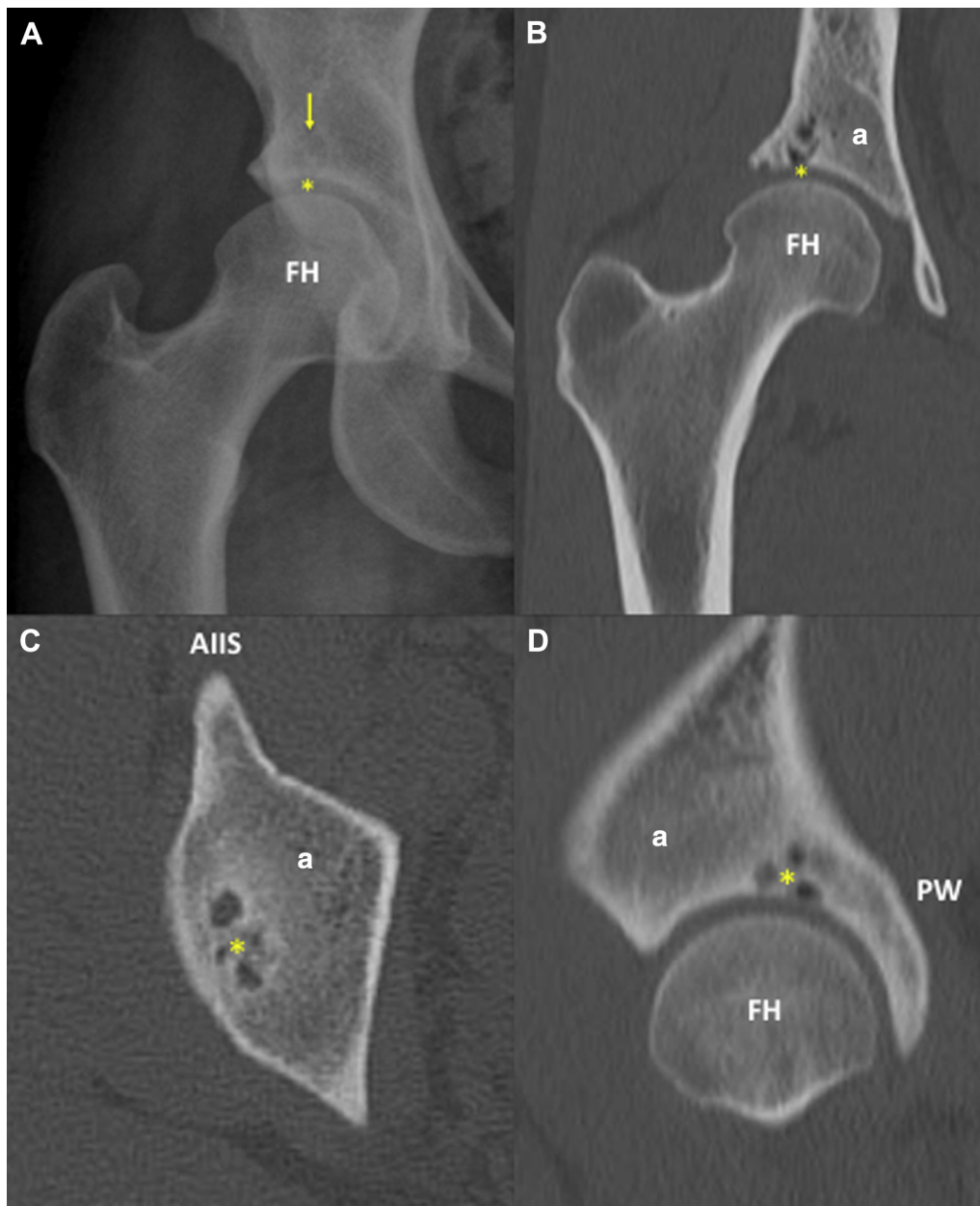


Fig 1. Preoperative radiographic studies. (A) AP radiograph of the right hip demonstrating a large acetabular bone cyst (yellow arrow) with articular communication (yellow asterisk). (B) Coronally reformatted computed tomography (CT) scan of the right hip demonstrating a loculated acetabular cyst with clear articular communication (yellow asterisk). (C) Axial CT scan of the right hip demonstrating an acetabular bone cyst with loculated appearance (yellow asterisk). (D) Sagittally reformatted CT scan of the right hip demonstrating a loculated acetabular bone cyst in the superior weight-bearing region (yellow asterisk). (a, acetabulum; AIIS, anterior inferior iliac spine; FH, femoral head; PW, posterior wall.)

performed as indicated, before turning attention to the treatment of the cyst.

Cyst Decompression and Bone Grafting

The damaged cartilage is sharply excised using angled curettes (Bruns Bone Curette Angled #1, Sklar Instruments, West Chester, PA) and shavers (Fig 2 B and C), and the underlying articular breach is exposed with an appropriately angled microfracture awl (XL Microfracture

Awl, Smith & Nephew, Andover, MA) (Fig 2D, Video 1). Mucinous cystic contents may be seen draining from the cyst cavity during this step (Video 1). A curved arthroscopic shaver (4.5 mm 30° angled double-bite, Stryker, Kalamazoo, MI) is then inserted through either the mid-trochanteric portal or the mid-anterior portal, and bluntly introduced into the opening of the cyst cavity to completely evacuate the contents. The shaver, curette, and microfracture awl are used in an alternating fashion

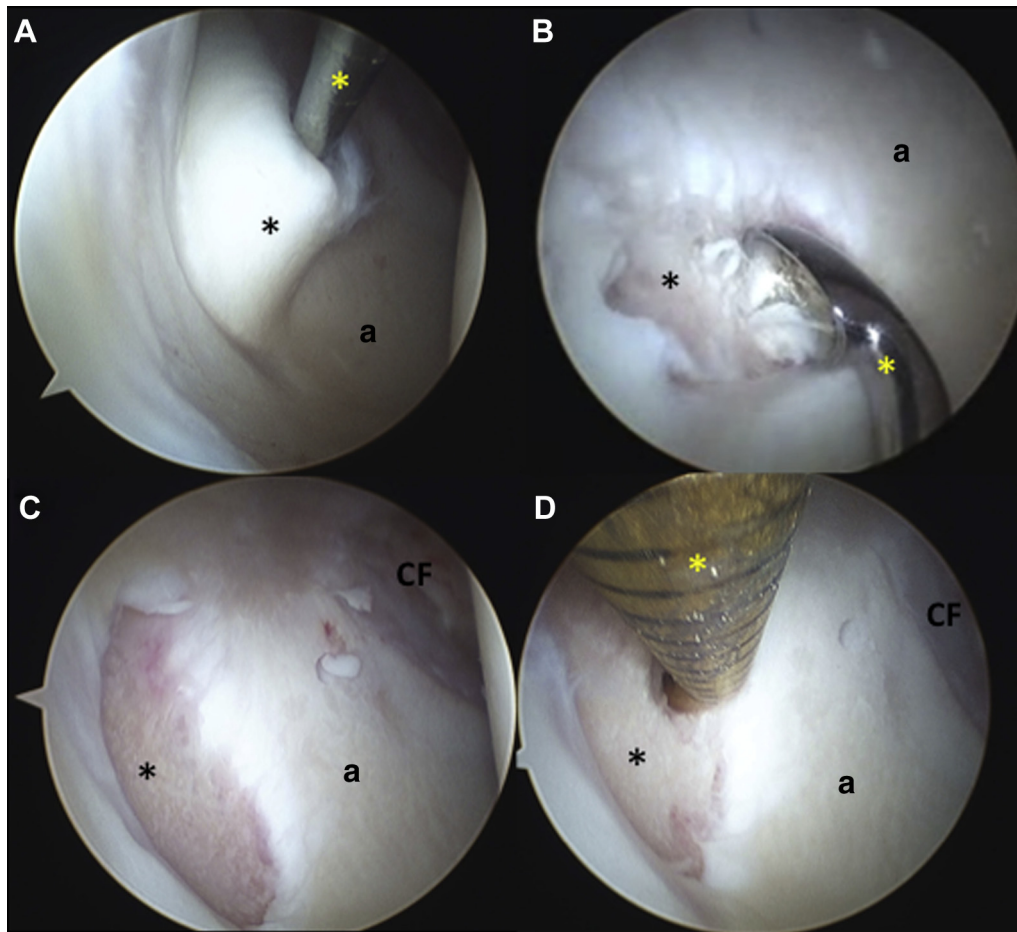


Fig 2. Intraoperative arthroscopic images corresponding to the right hip in [Figure 1](#). (A) Viewing through the mid-trochanteric portal with a 30° arthroscope, the full-thickness articular cartilage flap (black asterisk) is gently elevated with a probe (yellow asterisk) inserted through the mid-anterior portal. The articular cartilage flap covers the underlying acetabular bone cyst. (B) Viewing through the mid-anterior portal with a 30° arthroscope, an angled curette (yellow asterisk) is inserted through the mid-trochanteric portal to remove the calcified cartilage layer from the articular cartilage defect and to establish a stable rim. The articular communication of the cystic contents (black asterisk) is seen adjacent to the curette. (C) Viewing through the mid-trochanteric portal with a 30° arthroscope, the well-contained articular cartilage defect is seen (black asterisk) after removal of the overlying full-thickness cartilage flap. (D) Viewing through the mid-trochanteric portal with a 30° arthroscope, an angled microfracture awl (yellow asterisk) is inserted through the mid-anterior portal to gently probe and excavate the mucinous contents from the cystic cavity, adjacent to the articular cartilage defect (black asterisk). (a, acetabulum; CF, cotyloid fossa.)

to prepare the defect for bone grafting. Care is taken to ensure that all soft tissue contents have been evacuated from the cyst cavity. Microfracture may be carried out in the remainder of the bony defect to stimulate healing adjacent to the cystic breach. We recommend the additional use of a fluted drill for more accurate placement of microfracture holes into the cystic cavity (Micro FX, Stryker). Fluoroscopy may be used to assess the depth and adequacy of device penetration into the cyst cavity.

The arthroscopic shaver is then disassembled into an inner cutting sleeve, to be used as a plunger, and an outer sheath, to be used as the curved delivery device ([Fig 3 A and B](#)). This is accomplished by firmly applying manual pressure on the curved portion of the shaver against the sterile back table to slightly reduce the angle of curvature. This allows the inner sleeve to be removed

with relative ease ([Fig 3A](#)). The outer sleeve is cleaned with a cotton swab and used as a curved cannula for delivery of bone graft material into the cyst ([Fig 3 B-E](#)). The bone graft of choice (DBX, Synthes, West Chester, PA) is loaded antegrade into the outer sleeve by using the inner sleeve and/or blunt switching stick as a plunger until the material is seen at the aperture on the opposite end ([Fig 3 B and C](#)). The plunger is gently depressed while the surgeon occludes the aperture with his thumb, to pack the bone graft within the sheath, before introducing the sheath into the joint. The outer sheath may then be manipulated against the back table to the desired degree of curvature before inserting into the joint for bone graft application. A switching stick is used to assess the best portal for optimal trajectory to the cyst. A slotted cannula is then inserted over the

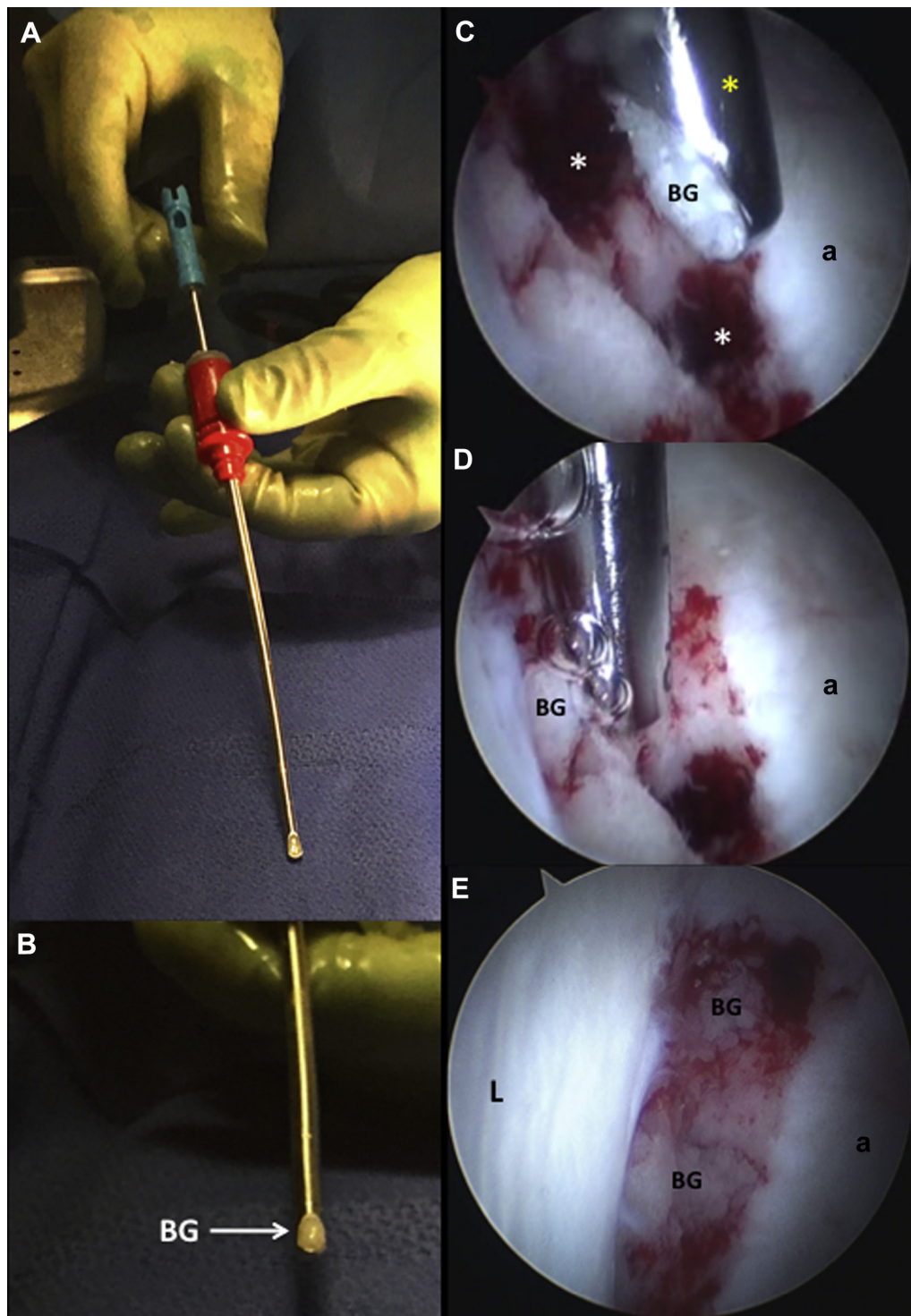


Fig 3. Sheath disassembly and intraoperative arthroscopic images corresponding to the right hip in Figure 1. (A) The curved shaver is disassembled by applying pressure against the sterile back table until the angle of curvature is slightly reduced. This allows the inner sleeve (blue) to be removed from the outer sheath (red) with relative ease. (B) The outer sheath is loaded with bone graft (BG), and the inner sleeve is used as a plunger until the bone graft can be seen exiting the side-opening. The outer sheath may then be manipulated against the back table to the desired degree of curvature before inserting into the joint for bone graft application. (C) Viewing through the mid-trochanteric portal with a 30° arthroscope, a curved shaver sleeve (yellow asterisk) loaded with bone graft is inserted through the mid-anterior portal in preparation for bone grafting of the cystic cavities (white asterisks). (D) Viewing through the mid-trochanteric portal with a 30° arthroscope, a curved shaver sleeve (yellow asterisk) is placed with the side-opening of the shaver sleeve facing the cystic cavity to deliver the bone graft. Air bubbles are seen as the inner sleeve of the curved shaver is deployed as a plunger to deliver the bone graft and pressurize the cystic cavity. (E) Viewing through the mid-anterior portal with a 30° arthroscope, a well-positioned bone graft can be seen within the loculated cystic cavity in the well-contained articular cartilage defect. (a, acetabulum; L, labrum.)

Table 1. Indications, Contraindications, and Technical Pearls for Inside Out Bone Grafting of Acetabular Intraosseous Cysts**Indications**

- Symptomatic hip instability or femoroacetabular impingement (FAI) with magnetic resonance imaging (MRI) and or computed tomography (CT) evidence of an acetabular intraosseous cyst

Contraindications

- Coxarthrosis (Tonnis grade 3 or 4)—Consider total hip arthroplasty

Technical pearls

- Use a blunt probe to gently expose the cyst by manipulating overlying delaminated articular cartilage
- Take time to completely excise the membranous cyst lining to prevent recurrence and failure of bony healing
- Use the portal that gives the best trajectory for delivering bone graft
- Perform grafting in stages and use multiple loads, if necessary, to adequately pressurize cyst
- Meticulously lavage and suction excess bone graft material from the joint
- Appropriately address all underlying pathomechanical contributors to cyst formation including femoroacetabular impingement and dysplasia

Potential risks

- Extravasation of bone graft material, possibly resulting in heterotopic ossification (HO)

switching stick, which is replaced by the curved shaver sleeve with bone graft inside. The aperture of the shaver sleeve is positioned at the opening of the cystic cavity, establishing a seal (Fig 3D). This is made possible by the “side opening” design of the sleeve, as compared with an “end opening” design of a typical cannula. The inner sleeve is used as a plunger to gently fill the cyst with bone graft. Turning the sheath 180° enables the surgeon to use its convex side to gently compact the bone graft. For larger cysts, the steps above are repeated to deliver more bone graft. After compacting the bone graft placed inside the cyst, excess graft is evacuated from the joint using a shaver placed away from the cyst region and traction is released. Table 1 outlines some important “technical pearls” for successful execution of this technique.

Postoperative Management

Postoperative precautions are predicated on the size and location of the cyst as well as any underlying dysplastic characteristics. We recommend limiting weight bearing to “toe-touch” for 4 to 6 weeks in patients with dysplasia or cysts $> 1 \text{ cm}^3$. Smaller cysts in patients with FAI may be treated with weight bearing as tolerated using crutches for stability for 2 weeks, provided that extensive microfracture was not performed. Standard hip arthroscopy rehabilitation is then commenced with return to play allowed 4 to 6 months postoperatively, depending on the duration of limited weight bearing and ability to regain muscle strength and control. Follow-up MRI may be obtained to ensure

adequate cyst healing (Fig 4), especially if a staged realignment procedure, such as a periacetabular osteotomy, is planned.

Discussion

In this article, we present an “inside-out” technique for bone grafting acetabular intraosseous cysts, using a curved delivery device. Some important advantages of this technique include preservation of the extra-articular cyst wall for more effective cyst pressurization with bone graft as well as obviating the need for concomitant rim trimming to afford cyst access. Given that these cysts are frequently encountered in patients with dysplasia, avoiding rim trimming for cyst access is highly beneficial. Potential risks associated with this technique include extravasation of bone graft material, possibly resulting in heterotopic ossification.

The prevailing approach for smaller cysts ($< 1 \text{ cm}^3$) entails evacuating the cystic contents, removing the lining, and stimulating osseous healing via abrasion chondroplasty or microfracture.^{4,5} Larger cysts ($> 1 \text{ cm}^3$) have been addressed exclusively with “outside-in” drilling using open⁴ and arthroscopic techniques,⁵ necessitating the creation of a second, extra-articular, breach into the cyst contents.

In the arthroscopic technique by Jamali et al.,⁵ this “outside-in” approach necessitates rim trimming to allow extra-articular access to the cyst contents, which may be ill advised in patients with normal coverage or dysplasia. Field et al.⁴ describe a technique using fluoroscopic guidance with a drill guide placed through the ilium. The position of the guide may be intrapelvic and extrapelvic depending on the location of the cyst and best trajectory for access. This technique carries the added morbidity of using a second incision and intrapelvic placement of the drill guide. In addition, the technique relies on image guidance for appropriate cyst localization rather than direct visualization, which may result in incomplete decompression and suboptimal placement of bone graft. In general, “outside-in” techniques provide indirect access for cyst lining removal and may result in persistent pain or cyst recurrence.

The curved delivery device described in this article is unique in that, with the use of appropriate portals, it allows direct access to all acetabular bone cysts. In addition, the limited side-opening of the sheath may be nicely apposed to the cyst introitus to create a seal for superior pressurization, concomitantly limiting extravasation of bone graft material into the joint cavity.

In summary, the “inside-out” technique described in this article may be universally applied to decompress and bone graft large ($> 1 \text{ cm}^3$) acetabular bone cysts. The technique allows for direct visualization of cyst

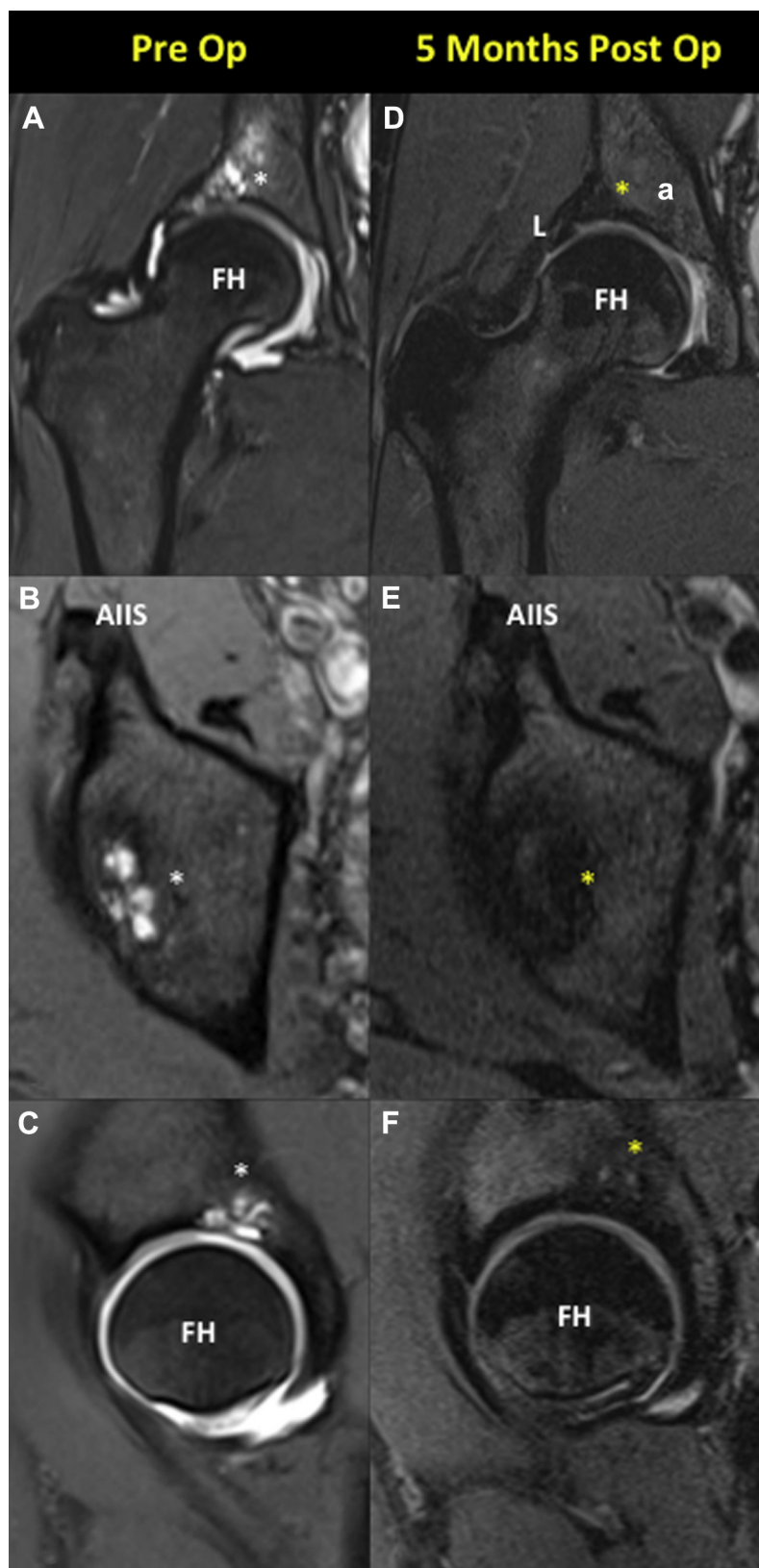


Fig 4. Pre- and postoperative magnetic resonance imaging (MRI) scans of the right hip, previously shown in [Figure 1](#). (A) Preoperative coronal T2 MRI arthrogram demonstrating an acetabular bone cyst (white asterisk) in the superior weight-bearing portion. (B) Preoperative axial T2 MRI arthrogram demonstrating an acetabular bone cyst (white asterisk) with the loculated pattern. (C) Preoperative sagittal T2 MRI arthrogram demonstrating an acetabular bone cyst (white asterisk) with articular cartilage breach. (D) Postoperative coronal T2 MRI scan demonstrating complete cyst healing and remodeling (yellow asterisk) with excellent fibrocartilage fill of articular cartilage defect. (E) Postoperative axial T2 MRI scan demonstrating complete cyst healing and remodeling (yellow asterisk) with resolution of loculations. (F) Postoperative sagittal T2 MRI scan demonstrating complete cyst healing and remodeling (yellow asterisk) with excellent fibrocartilage fill of articular cartilage defect. (a, acetabulum; AIIS, anterior inferior iliac spine; FH, femoral head; L, labrum.)

decompression, preservation of the extra-articular cyst wall, and pressurization of bone graft.

References

1. Inui A, Nakano S, Yoshioka S, et al. Subchondral cysts in dysplastic osteoarthritic hips communicate with the joint space: Analysis using three-dimensional computed tomography. *Eur J Orthop Surg Traumatol* 2013;23:791-795.
2. Register B, Pennock AT, Ho CP, Strickland CD, Lawand A, Philippon MJ. Prevalence of abnormal hip findings in asymptomatic participants: A prospective, blinded study. *Am J Sports Med* 2012;40:2720-2724.
3. Tzaveas AP, Villar RN. Cyst-like lesion of the acetabular roof—An abnormal finding or an anatomical variant? *Hip Int* 2010;20:258-260.
4. Field RE, Rajakulendran K, Strambi F. Arthroscopic grafting of chondral defects and subchondral cysts of the acetabulum. *Hip Int* 2011;21:479-486.
5. Jamali AA, Fritz AT, Reddy D, Meehan JP. Minimally invasive bone grafting of cysts of the femoral head and acetabulum in femoroacetabular impingement: Arthroscopic technique and case presentation. *Arthroscopy* 2010;26:279-285.
6. Mei-Dan O, McConkey MO, Young DA. Hip arthroscopy distraction without the use of a perineal post: Prospective study. *Orthopedics* 2013;36:e1-e5.