

## Technical Note

# Eversion-Inversion Labral Repair and Reconstruction Technique for Optimal Suction Seal

Brett Moreira, M.B.B.S., Cecilia Pascual-Garrido, M.D., Vivek Chadayamurri, M.D.,  
and Omer Mei-Dan, M.D.

**Abstract:** Labral tears are a significant cause of hip pain and are currently the most common indication for hip arthroscopy. Compared with labral debridement, labral repair has significantly better outcomes in terms of both daily activities and athletic pursuits in the setting of femoral acetabular impingement. The classic techniques described in the literature for labral repair all use loop or pass-through intrasubstance labral sutures to achieve a functional hip seal. This hip seal is important for hip stability and optimal joint biomechanics, as well as in the prevention of long-term osteoarthritis. We describe a novel eversion-inversion intrasubstance suturing technique for labral repair and reconstruction that can assist in restoration of the native labrum position by re-creating an optimal seal around the femoral head.

The integrity of the acetabular labrum is crucial to normal biomechanics of the hip joint.<sup>1</sup> The acetabular labrum is a fibrocartilaginous structure that acts as an extension of the bony acetabular rim. It runs around the circumference of the acetabulum, forming a labral suction seal. This hip suction seal is theorized to be important to normal hip function and kinematics.<sup>2</sup> Current evidence suggests that the hip fluid seal is important for intra-articular fluid pressurization and hip stability.<sup>3</sup>

Damage to the acetabular labrum is responsible for a reduction in function and increased potential damage to articular cartilage, potentially predisposing the hip to osteoarthritis.<sup>4</sup> The current gold standard of treatment of labral tears is labral preservation, primarily in the form of labral repair.<sup>2</sup> A suture anchor is most commonly used to reattach the torn labrum to the "new" acetabular rim after resection of pincer lesions,<sup>5</sup>

with controversy over the ideal technique to achieve the optimal refixation position and anatomic restoration of cross-sectional labral triangular geometry.<sup>6</sup>

Previously described repair techniques have involved suture placement, using either loop-fashion or pass-through intrasubstance sutures in an attempt to form a gasket for the joint, by restoring the labrum against the femoral head.<sup>7</sup> However, with the use of most of the available knotted and knotless anchors, both loop-fashion and pass-through intrasubstance techniques may still inadvertently invert or evert the labrum during the repair process because of the inability to separately adjust the suture limbs' tension and labral position. We describe an eversion-inversion labral repair and reconstruction technique that restores an optimal labral suction seal (Table 1). The technique is based on the base pass-through technique and an anchor that enables a unique eversion-inversion motion, fine-tuning the repaired labral seal, even if not positioned on the rim edge at the chondrolabral junction itself.

## Surgical Procedure

The patient is positioned supine on a surgical table, with the feet well padded and placed into traction boots (Video 1). After sterile preparation and draping, traction is applied and a spinal needle is used to break the suction seal of the hip. When adequate joint distraction is obtained, an anterolateral portal is made with the aid of fluoroscopy and the arthroscope is introduced into the hip. An anterior portal is then made under direct vision, and an intraportal capsulotomy is made, allowing diagnostic arthroscopy to take place.

From Western Health (B.M.), Melbourne, Australia; and the Department of Orthopaedics, Division of Sports Medicine and Hip Preservation, University of Colorado (C.P.-G., V.C., O.M.-D.), Denver, Colorado, U.S.A.

The authors report the following potential conflict of interest or source of funding: O.M.-D. receives support from Smith & Nephew.

Received March 8, 2015; accepted July 14, 2015.

Address correspondence to Omer Mei-Dan, M.D., Department of Orthopaedics, Division of Sports Medicine and Hip Preservation, University of Colorado School of Medicine, 12631 E 17th Ave, Mail Stop B202, Academic Office 1, Room 4602, Aurora, CO 80045, U.S.A. E-mail: [omer.meidan@ucdenver.edu](mailto:omer.meidan@ucdenver.edu)

© 2015 Arthroscopy Association of North America. Published by Elsevier Inc. All rights reserved.

2212-6287/15226/\$36.00

<http://dx.doi.org/10.1016/j.eats.2015.07.005>

**Table 1.** Technical Pearls for Labral Repair With Eversion-Inversion Technique

---

Proper orientation of the suture anchor should be ensured (the drilling trajectory should always be away from the cartilage surface, under direct vision).

There is no need to drill the anchor too close to the rim's edge, as with knotted anchors.

The surgeon should drill all anchor holes first and then move to sequential anchor placement.

A slotted cannula can be used to avoid tissue bridging and guide the suture passer or suture anchor to the required area. This will protect it from bending or breaking because of an awkward working angle.

The suture limbs are best retrieved with a small-diameter suture passer.

The surgeon must ensure that there is enough labral tissue between the entry points at the CLJ and intralabral suture to allow firm fixation.

When performing tensioning using knotless anchors, the surgeon should tension the lower (CLJ) suture limb first to bring the labral tissue closer to the actual bony rim origin. Second, he or she should tension the upper (labral tissue) suture limb to achieve the eversion-inversion optimal position. The anchor can then be locked when the surgeon is happy.

The surgeon should perform a thorough examination of the labral suction seal on the femoral head during and at the end of the procedure. An unstable labrum must be corrected to prevent subsequent damage to the labrum and adjacent articular cartilage.

In case the labrum is excessively everted or inverted, the suture limbs can be easily loosened using a common arthroscopic probe.

Adequate traction across the hip joint should be achieved and accurate portal placement ensured for optimal visualization of the damaged labrum.

---

CLJ, chondrolabral junction.

When a labral tear is identified, it is assessed to determine the most appropriate repair technique needed. This includes the need for rim resection or anterior inferior iliac spine reduction (or both). Even if the patient is known to have a completely detached labrum or large pincer lesion, which needs to be addressed, the eversion-inversion technique can still be used. Judicious rim trimming must be performed so as not to worsen the pathologic undercoverage found in a dysplastic or borderline dysplastic hip. The goal is not to further contribute to pre-existing instability and potentially compromise the ability to obtain an optimal seal because of dysmorphic anchoring points.

To expose the acetabular rim for anchor drilling and repair, the labrum is separated from the capsule and undermined gently from the rim with a radiofrequency wand (Multivac 50; ArthroCare, Austin, TX). A shaver (Double Bite; Stryker, Kalamazoo, MI) is used to debride the torn chondrolabral junction and reactive tissue. Formal burring is performed with a 4-mm unhooded burr (Stryker) around the rim, at the clock-face positions where the anchors will be placed. Further burring is performed to reduce pincer bone and generate a bleeding bed of bone to facilitate revascularization for healing. Anchors are drilled at the exposed and prepared rim, between the labrum and capsule origins. One of the

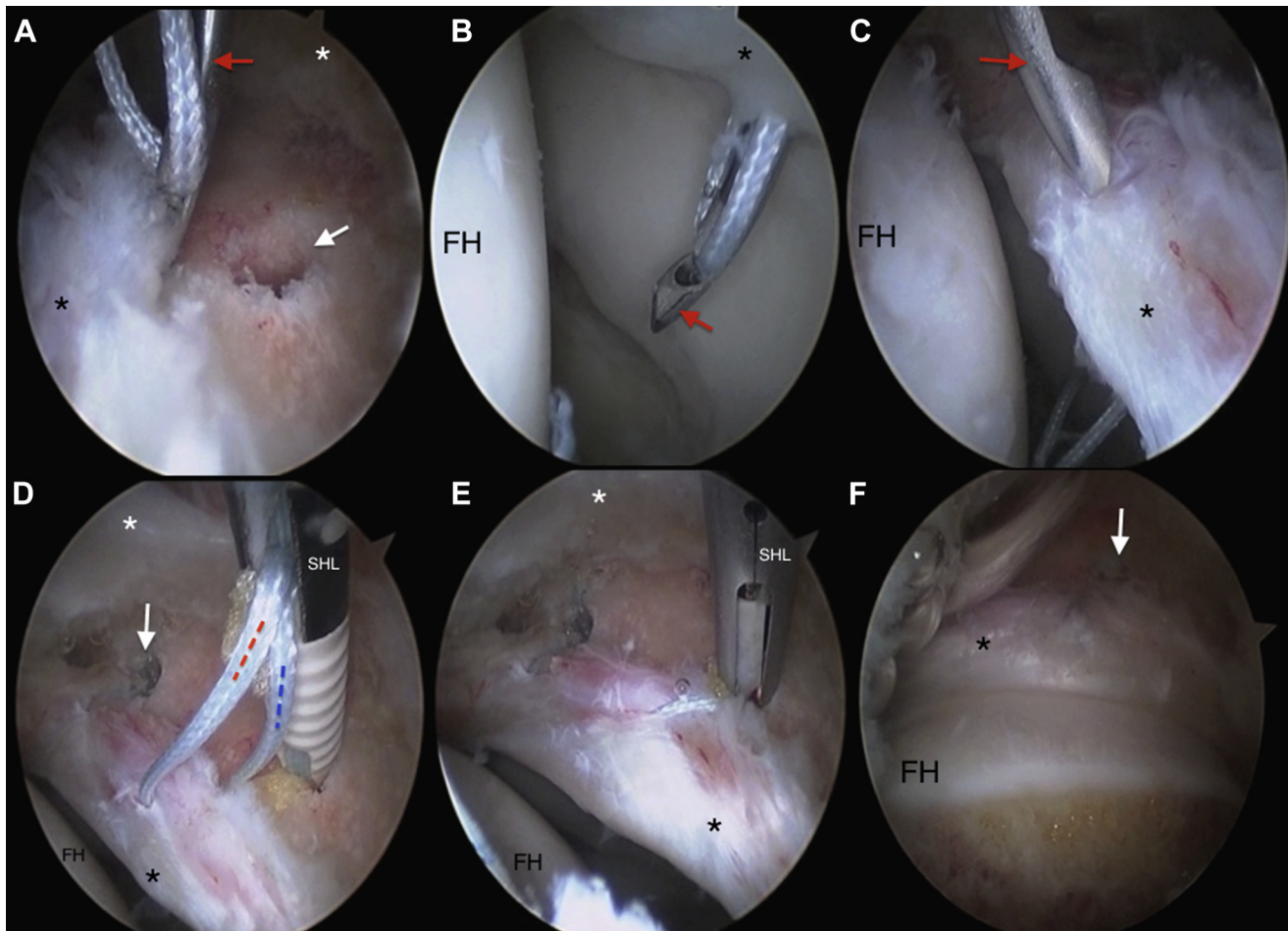
advantages of the described technique is that there is no need to drill the anchor too close to the rim's edge, as is required when using knotted anchors. This parameter can prevent the potential complications of subchondral drilling and anchor placement.

Once the final number and location of anchors are determined, a guide is placed against the acetabular rim at the desired location, and a drill hole for the anchor is made. We tend to drill all anchor holes first and then move to sequential anchor placement. The first suture pass penetrates the chondrolabral junction using an arthroscopic suture passer (Pivot Nano-Pass; Pivot Medical, Sunnyvale, CA) from the capsular side, which grasps the suture 3 inches from its end. From this point, a suture loop of 3 inches is then left under the labrum. The suture passer re-enters through the actual labral tissue on its capsular side, with the surgeon making sure enough tissue is left between the 2 suture penetrations to hold a firm repair. The suture loop is retrieved from the intra-articular cartilage surface and pulled all the way out. At this stage, both suture limbs are passed through the labrum in a mattress fashion and are ready to be loaded into the anchor (Hip SpeedLock; ArthroCare). The suture is loaded by the described technique (Fig 1, Video 1), and the anchor is introduced into the joint, fitted into the predrilled hole, and tapped until it is well seated. The repair process is performed with a slotted or plastic cannula to avoid tissue bridging while the anchor is inserted.

Once the anchor has been seated, the suture limbs are tensioned separately (Video 1), allowing the labrum to evert peripherally and invert at the chondrolabral junction. First, the lower (chondrolabral junction) suture limb is tensioned, which results in bringing the labral tissue closer to the actual bony rim origin. Then, the upper (labral tissue) suture limb is tensioned to achieve the eversion-inversion optimal position. Once the surgeon is happy with the obtained labral tissue position, the anchor can be locked.

Before the anchor is locked and in case the labrum has been overly everted or inverted, the suture limbs can be easily loosened using a common arthroscopic probe. In addition, in some cases it is advised to release hip distraction before locking the anchor to evaluate and ensure that a proper seal is created around the femoral head by the repaired labrum. Further eversion-inversion adjustments and the final locking maneuvers can be performed at that time as well.

When the labrum is fully separated from the acetabular rim, as in the case of extensive rim trimming or a complete bucket-handle tear, a slight modification in suture passing is required whereas anchor positioning and handling remain as described earlier. It is much harder to pass a suture through a "floating" labrum using common suture passers unless the detached section is small. In these scenarios, we use the SpeedStitch



**Fig 1.** The labral repair sequence is shown in a single case, with the camera in the mid-trochanteric portal. The anterior portal is used for instrumentation access. Black asterisks indicate the labrum, and white asterisks indicate the capsule. (A) The Nano-Pass suture passer (red arrow) is used to shuttle an ultrahigh-strength suture through the base of the labrum at the chondrolabral junction. The backside (convex side) of the Nano-Pass should “ride” over the bony rim to enter the chondrolabral junction just in front of the predrilled anchor hole (white arrow). (B) The same suture pass, using the Nano-Pass (red arrow), enters through the chondrolabral junction into the hip joint. (C) The role of the second suture pass is to complete the suture grab through the base of the labrum. It starts at the mid portion of the capsular side of the labrum, leaving a large tissue bridge between the first and second bites, for a strong repair and firm tissue hold. It is best if the second pass of the Nano-Pass (red arrow) exits at the same chondrolabral junction made by the first pass, or very close to it. (D) The Hip SpeedLock anchor (SHL) is seated into the predrilled hole. One should note that the suture-passing points should be aligned with the predrilled hole. There is intentional slack of suture as the anchor is tapped into the hole. This slack is vital to obtain controlled tensioning of the labrum and is the hallmark of the inversion-eversion technique. We always start with the bottom suture first (rim side, blue dashed line), tightening the labral base to the bony rim, followed by the top suture (red dashed line), which controls the eversion-inversion final position. The first (most medial) anchor is seen in the background (white arrow). (E) The acetabular labrum is positioned to form an optimal suction seal. The SHL anchor is ready to be locked. The suture can be seen securing the base of the labrum to the bony rim. (F) A complete labral repair and optimal suction seal are achieved and are maintained when traction is released. The white arrow points to the SHL anchor position in the bony rim. The femoral head-neck junction is seen after femoral osteoplasty to reduce cam impingement. (FH, femoral head.) © 2015 Omer Mei-Dan. All Rights Reserved.

device (ArthroCare) to grasp and pass the suture through the labrum at the same time, using the technique described by Mei-Dan and Young.<sup>8</sup> We use the SpeedStitch device, a grasping-passing device, and the aforementioned eversion-inversion technique to secure and optimally adjust the obtained seal for our labral reconstruction procedures as well.

The remainder of the surgical procedure continues as with any standard hip arthroscopy, with release of hip distraction and evaluation of the peripheral compartment and repaired labrum. Osteoplasty is undertaken as required, and impingement is dynamically assessed. We repair the capsule at the completion of the procedure in most cases.



## Discussion

Labral repair can improve both patient symptoms and function in the short-term and allows the high-level athlete to return to sports. Successful labral repair may delay or protect the hip joint from osteoarthritis development in the long-term.<sup>5</sup>

The presence of a fluid seal in the hip has been established for many years.<sup>9</sup> In theory, intra-articular fluid pressurization during compressive loads has been reported to protect the cartilage matrix and decrease the friction between the two surfaces.<sup>10</sup> With distraction forces on the hip, the hip fluid seal creates negative intra-articular pressure (suction effect) that resists displacement of the femoral head. Both functions of the hip fluid seal are currently theorized to be reliant on an intact acetabular labrum.<sup>6,11</sup>

Historically, there has been contentious debate over the method for maintenance of the natural triangular cross-sectional geometry of the labrum.<sup>6,11</sup> Fry and Domb<sup>11</sup> used a knotless technique for the labral base stitch configuration, thus avoiding any potential abrasion of the articular cartilage by knots. Other authors, advocating for the looped simple stitch technique, were still able to show restoration of the triangular fibrocartilage configuration of the labrum with what they believe will result in strong fixation, using knots.<sup>6</sup> However, in their technique using push-lock anchors, there is no ability to adjust or control suture tension separately for each suture limb going through the anchor after the anchor is fully seated. Even when the labrum is grabbed at its base, it may still be everted away from the joint surface, and when traction is removed, there will be a gap surrounding the femoral head. Thus, even if the triangular cross-sectional geometry of the labrum is maintained, it is not congruent with the femoral head and the repair is nonfunctional.

Our technique has the advantages of both of the aforementioned techniques without the disadvantages. The absence of a knot in our method reduces scar tissue formation and potential capsulolabral adhesions or iatrogenic chondral damage to the femoral head. In contrast to the ability to control a single suture limb using arthroscopic knots with a post, our knotless technique successfully controls both suture limbs' tension separately for optimal labral positioning and restoration of the optimal suction seal.

Two recent studies advocated the use of pass-through intrasubstance labral sutures for arthroscopic labral repair.<sup>1,12</sup> Both Ye and Singh<sup>1</sup> and Stubbs et al.<sup>12</sup> aimed to avoid eversion of the labral tissue during the repair process. Likewise, our method uses a fine-tuning technique to control proper eversion and inversion of the labral tissue to avoid pulling the repaired labrum from the femoral head and compromising its seal function.

Our labral repair method differs from those of the previous authors because our technique aims for both

eversion and inversion of the labrum to restore both the native chondrolabral interface and the optimal tissue position in space. This creates a robust and optimal seal around the femoral head and restores normal anatomic function.

The technique is safe and reproducible overall but requires practice and attention to be performed safely and effectively. The eversion-inversion method described in this article provides an alternative method for labral repair, using standard approaches and operative techniques, allowing for restoration of the physiological suction seal while maintaining the native labrum.

## References

1. Ye K, Singh P. Arthroscopic labral repair of the hip, using a through-labral double-stranded single-pass suture technique. *Arthrosc Tech* 2014;3:e615-e619.
2. Philippon M, Nepple J, Campbell K, et al. The hip fluid seal—Part I: The effect of an acetabular labral tear, repair, resection, and reconstruction on hip fluid pressurization. *Knee Surg Sports Traumatol Arthrosc* 2014;22:722-729.
3. Philippon M, Nepple J, Campbell K, et al. The hip fluid seal—Part II: The effect of an acetabular labral tear, repair, resection, and reconstruction on hip stability to distraction. *Knee Surg Sports Traumatol Arthrosc* 2014;22:730-736.
4. Sankar WN, Nevitt M, Parvizi J, Felson DT, Agricola R, Leunig M. Femoroacetabular impingement: Defining the condition and its role in the pathophysiology of osteoarthritis. *J Am Acad Orthop Surg* 2013;21:S7-S15 (suppl 1).
5. Philippon M, Faucet S, Briggs K. Arthroscopic hip labral repair. *Arthrosc Tech* 2013;2:e73-e76.
6. Lertwanich P, Ejnisman L, Philippon M. Comments on "Labral base refixation in the hip: Rationale and technique for an anatomic approach to labral repair." *Arthroscopy* 2011;27:303-305.
7. Philippon M, Peixoto L, Goljan P. Acetabular labral tears: Debridement, repair, reconstruction. *Oper Tech Sports Med* 2012;20:281-286.
8. Mei-Dan O, Young D. A novel technique for capsular repair and labrum refixation in hip arthroscopy using the SpeedStitch. *Arthrosc Tech* 2012;1:e107-e112.
9. Philippon M, Ferro F, Nepple J. Hip capsulolabral spacer placement for the treatment of severe capsulolabral adhesions after hip arthroscopy. *Arthrosc Tech* 2014;3:e107-e112.
10. Song Y, Ito H, Kourtis L, Safran M, Carter D, Giori N. Articular cartilage friction increases in hip joints after the removal of acetabular labrum. *J Biomech* 2012;45:524-530.
11. Fry R, Domb B. Labral base refixation in the hip: Rationale and technique for an anatomic approach to labral repair. *Arthroscopy* 2010;26:S81-S89.
12. Stubbs A, Andersen J, Mannava S, Wooster B, Howse E, Winter B. Arthroscopic hip labral repair: The Iberian suture technique. *Arthrosc Tech* 2014;3:e351-e354.