



A commentary by **Stuart C. Marshall, MD,** and **S. Charles Marshall Jr., MD,** is linked to the online version of this article at [jbjs.org](http://jbjs.org).

# Femoral Version Abnormalities Significantly Outweigh Effect of Cam Impingement on Hip Internal Rotation

Matthew J. Kraeutler, MD, Vivek Chadayammuri, MD, Tigran Garabekyan, MD, and Omer Mei-Dan, MD

*Investigation performed at the CU Sports Medicine and Performance Center, Department of Orthopedics, University of Colorado School of Medicine, Boulder, Colorado*

**Background:** The purpose of this study was to investigate the effects of femoral version, cam-type femoroacetabular impingement (FAI), and the combination of the 2 on the passive hip range of motion (ROM).

**Methods:** We prospectively analyzed a consecutive cohort of 220 patients (440 hips) who presented with unilateral or bilateral hip pain. The passive hip ROM was measured bilaterally with the patient in prone, supine, and lateral positions. Femoral version was measured and the presence of cam-type deformity was determined on preoperative computed tomography (CT) scans. Diagnostic findings of cam-type FAI included an alpha angle of  $>50^\circ$  on CT radial sequences of the head-neck junction and a femoral head-neck offset ratio of  $<0.18$  on both radiographs and CT.

**Results:** Multivariate linear regression analysis confirmed that femoral version, as compared with the presence of a cam lesion, was a stronger independent predictor of internal rotation ROM. Conversely, the presence of a cam lesion resulted in a significant decrease in the passive hip flexion ROM ( $p < 0.001$ ) with no additional effects due to the degree of femoral version. The passive hip internal rotation ROM in neutral flexion/extension and with the hip in  $90^\circ$  of flexion were maximized in patients with femoral anteversion and decreased significantly with each incremental decrease in femoral version ( $p < 0.001$ ).

**Conclusions:** Abnormalities in femoral version significantly outweigh the effect of cam-type impingement on the passive hip internal rotation ROM. In contrast, the presence of a cam lesion significantly decreases the hip flexion ROM, irrespective of the degree of femoral version. These findings help to inform surgical decision-making for patients with cam-type FAI or femoral version abnormalities.

**Clinical Relevance:** It is common clinical practice to ascribe loss of hip internal rotation to the presence of a cam lesion and to assume that arthroscopic femoral osteoplasty will substantially improve internal rotation postoperatively. Our study shows that the cam lesion is more intimately tied to hip flexion than to hip internal rotation. This result directly impacts the clinical assessment of a patient presenting with radiographic findings of FAI.

Femoroacetabular impingement (FAI) occurs most commonly in young adults and is highly associated with specific sports such as soccer and ice hockey<sup>1-3</sup>. This diagnosis can be divided into cam, pincer, and mixed types depending on whether the impingement is caused by the femoral head and/or the acetabular rim<sup>4</sup>. Several previous studies have shown that cam FAI, which occurs when a nonspherical extension of the femoral head causes impingement with the

articulating acetabular cavity<sup>4</sup>, reduces hip range of motion (ROM) compared with that seen in individuals without FAI<sup>5-8</sup>. However, some authors have questioned the role of the cam lesion in reducing the ROM, stating that the overall hip anatomy, specifically femoral version, should be analyzed rather than the presence or size of a cam lesion<sup>9</sup>. The purpose of this study was to investigate the effects of femoral version, cam-type FAI, and the combination of the 2 on passive hip ROM.

**Disclosure:** No external funding was used for this study. The **Disclosure of Potential Conflicts of Interest** forms are provided with the online version of the article (<http://links.lww.com/JBJS/E510>).

### Materials and Methods

After institutional review board approval was obtained, we performed a single-center prospective study of a consecutive cohort of 220 patients undergoing hip arthroscopy. The criteria for inclusion in this study were (1) persistent hip pain and mechanical symptoms refractory to nonoperative management (physical therapy, injections, and nonsteroidal anti-inflammatory drugs), (2) reproducible findings of clinical examinations (the impingement or FABER [flexion, abduction, and external rotation] test) suggesting impingement and/or instability, (3) pain alleviated by an intra-articular lidocaine injection, and (4) a joint space width of  $>3$  mm on all radiographic and 3-dimensional (3D) computed tomography (CT) views<sup>10</sup>. Common indications for hip arthroscopy were symptomatic FAI, hip instability due to dysplasia (prior to periacetabular osteotomy), and/or excessive femoral version (prior to derotational femoral osteotomy). Patients undergoing surgical treatment for diagnoses of slipped capital femoral epiphysis (SCFE), Legg-Calvé-Perthes disease, osteochondromatosis, or post-dislocation syndrome were excluded. Demographic

characteristics including diagnosis, age, sex, height, weight, and body mass index (BMI) were recorded for all patients.

### Clinical Examination

As part of a comprehensive clinical examination of the spine, hip, and pelvis<sup>11</sup>, the passive hip ROM was evaluated bilaterally with the patient in the supine, prone, and lateral positions. Passive hip flexion ROM and passive internal and external rotation ROM at 90° of hip flexion were measured following stabilization of the pelvis with the patient supine. Abduction was measured at a neutral hip position (0° of flexion/extension) with the patient supine. Internal and external rotation ROM with the hip in neutral flexion/extension was measured with the patient prone. All of these measurements were made several weeks prior to the imaging and were listed in each patient's chart so the clinical examiner was blinded to the version values for each patient.

### Imaging Technique

A standardized series of preoperative anteroposterior pelvic radiographs and CT scans was made. The anteroposterior pelvic

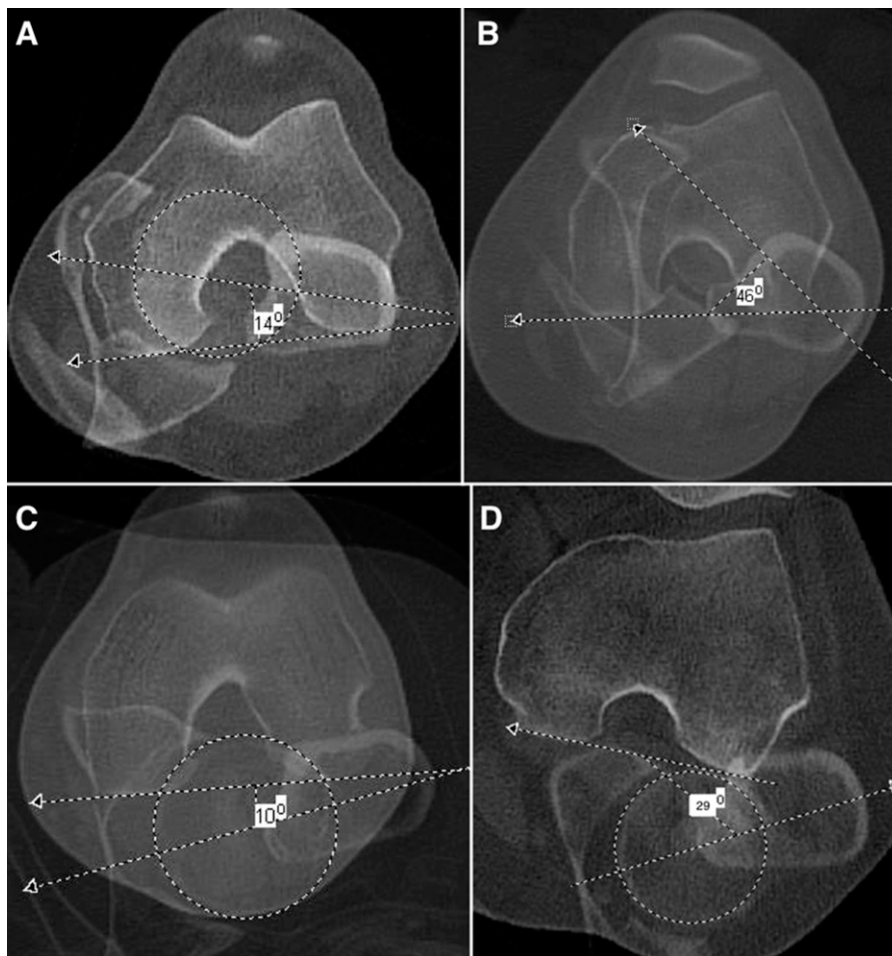


Fig. 1

**Figs. 1-A through 1-D** Femoral version measurements using overlapping axial CT images. **Fig. 1-A** Normal femoral version. **Fig. 1-B** Femoral anteversion. **Fig. 1-C** Mild femoral retroversion. **Fig. 1-D** Extreme femoral retroversion.

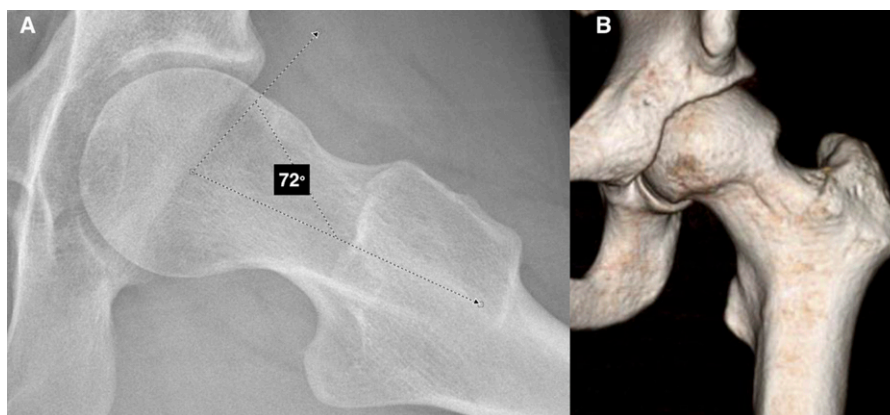


Fig. 2  
Cam lesion seen on a cross-table lateral radiograph with measurement of the alpha angle (**Fig. 2-A**) and on a 3D CT scan (**Fig. 2-B**).

radiograph was obtained with the patient positioned supine with the lower extremities internally rotated  $15^\circ$  to maximize femoral neck length. A radiograph was considered adequate if the obturator foramina were symmetric and the distance between the coccyx and pubic symphysis was 1.0 to 3.0 cm<sup>12-14</sup>.

CT scans were acquired in 1-mm-thick slices, with a 750-mm field of view from the iliac crests to the lesser trochanters and through the knee joints. Images were reconstructed in the axial, sagittal, coronal orthogonal, and oblique axial (oriented parallel to the long axis of the femoral neck) planes with a 2-mm slice thickness<sup>15</sup>. For all imaging modalities, the femoral head center was approximated using Mose templates<sup>16</sup>.

### Imaging Measurements

For the measurement of femoral version, axial CT images of the center of the femoral head, lesser trochanter, and distal femoral condyles were first overlapped. Femoral version was then determined as the angle between the femoral neck axis and the transcondylar axis (Fig. 1). Joint space width was defined as the narrowest distance between the osseous contour of the acetabular weight-bearing zone and the femoral head. The lateral center-edge angle (LCEA) was defined according to the modification described by Ogata et al.<sup>17</sup> as the angle between (1) a vertical line drawn through the center of the femoral head and orthogonal to the transverse line passing through the teardrops of both hips and (2) an oblique line drawn from the center of the femoral head to the lateral weight-bearing sclerotic zone (sourcil) of the acetabular rim. The LCEA was measured only for diagnostic purposes and was not incorporated into any statistical analyses.

All angular measurements were made using the digital calipers on the OfficePACS (Picture Archiving and Communication System; Stryker) by an examiner blinded to the clinical ROM measurements and the patient's sex. Femoral version was considered excessive (anteversion) if it was  $>20^\circ$ , normal if it was  $10^\circ$  to  $20^\circ$ , or reduced (retroversion) if it was  $<10^\circ$ . The presence of a cam lesion was determined by an alpha angle of  $>50^\circ$  on CT radial sequences of the head-neck junction and a femoral head-neck offset ratio of  $<0.18$  on both radiographs and CT (Fig. 2).

Clinical diagnoses of osseous impingement and/or acetabular dysplasia were determined according to accepted pathomorphologic signs and measurements<sup>15,18,19</sup>. Suggestive physical examination findings included a reduced hip flexion ROM, reduced internal rotation ROM, and/or positive provocative tests<sup>20</sup>. The diagnosis was confirmed by imaging findings of focal acetabular overcoverage as indicated by an LCEA of  $>40^\circ$  and/or a Tönnis angle of  $<0^\circ$  for pincer-type FAI, the presence of an anterior or lateral cam lesion for cam-type FAI, and an LCEA of  $<20^\circ$  and/or a Tönnis angle of  $>10^\circ$  for lateral acetabular dysplasia.

### Examiners

The degree of agreement between visual estimation and goniometric methods of measuring ROM was previously evaluated in a pilot study of 100 consecutive hips using a 2-way mixed, absolute-agreement single-measures intraclass correlation coefficient (ICC)<sup>21</sup>. The ICC was 0.976 (95% confidence interval [CI] = 0.727 to 0.992), indicating excellent reliability<sup>22</sup>. Therefore, all measurements of passive ROM in the present study were performed through visual estimation by a single experienced hip-preservation surgeon. CT measurements were made by a dedicated musculoskeletal radiology team composed of 3 fellowship-trained musculoskeletal radiologists.

TABLE I Patient Demographics and Baseline Characteristics

Patient Variables	Value
No. of patients (hips)	220 (440)
Mean age (SD) (yr)	32.4 (11.0)
Male sex (no. [%] of patients)	63 (28.6)
Mean height (SD) (cm)	169.7 (9.8)
Mean weight (SD) (kg)	70.0 (16.1)
Mean BMI* (SD) (kg/m <sup>2</sup> )	24.2 (4.6)
Cam lesion (no. [%] of hips)	206 (46.8)

\*Normal BMI = 18.00 to 24.99 kg/m<sup>2</sup>, overweight = 25.00 to 29.99 kg/m<sup>2</sup>, and obese  $\geq 30.00$  kg/m<sup>2</sup>.

TABLE II Effect of Femoral Version and Cam Impingement on Hip ROM

	Mean (SD)*						ANOVA P Value
	RV + WC	RV + NC	NV + WC	NV + NC	AV + WC	AV + NC	
Internal rotation at 90° of hip flexion	7.0 (7.6)	9.8 (7.6)	12.4 (8.3)	14.9 (8.2)	18.4 (10.8)	25.5 (13.3)	<0.001†
Internal rotation at neutral hip flexion/extension	23.3 (10.9)	24.9 (13.5)	28.2 (11.5)	33.0 (11.6)	38.2 (14.0)	41.9 (13.7)	<0.001†
External rotation at 90° of hip flexion	47.3 (4.4)	47.7 (5.0)	46.1 (4.0)	47.2 (4.1)	44.9 (6.5)	45.9 (4.4)	0.008†
External rotation at neutral hip flexion/extension	29.7 (13)	28.1 (10.7)	24.0 (9.0)	28.3 (11.0)	21.1 (10.0)	22.6 (10.7)	<0.001†
Abduction	43.4 (3.8)	43.3 (4.8)	43.9 (4.1)	43.8 (4.3)	43.0 (4.4)	43.8 (4.2)	0.822
Flexion	105.1 (10.1)	111.1 (11.7)	107.6 (10.7)	113.1 (12.3)	108.7 (11.1)	115.1 (13.0)	<0.001†

\*RV = femoral retroversion, WC = with cam lesion, NC = no cam lesion, NV = neutral femoral version, and AV = femoral anteversion,.. †Significant.

The assessors were blinded to each other's measurements to reduce the risk of measurement bias.

### Statistical Analysis

The distributions of all variables were evaluated for normality using a combination of histograms, quantile-quantile (Q-Q) plots, and Shapiro-Wilk tests. Descriptive statistics were summarized as means and standard deviations (SDs) for quantitative variables and as counts and frequencies for categorical variables. The significance of mean differences between independent groups was evaluated using the independent-samples t test, analysis of variance (ANOVA) with a post-hoc Tukey honest significant difference (HSD) or Games-Howell test, or the Kruskal-Wallis H test with a Dunn multiple-comparison post-hoc test. The overall effect of femoral version and of the presence of a cam lesion on passive hip internal rotation ROM was evaluated using a multivariate

linear regression model with a generalized estimating equation (GEE) approach and an unstructured correlation matrix. Significance for all comparisons was set at  $p < 0.05$  (2-tailed). All analyses were conducted using SPSS software (version 23.0; IBM).

## Results

### Participants and Descriptive Data

The study cohort comprised 220 patients (440 hips) with a mean age of 32.4 years (SD, 11.0 years) and a mean BMI of 24.2 kg/m<sup>2</sup> (SD, 4.6 kg/m<sup>2</sup>). Sixty-three patients (28.6%) were male. Of the 440 hips, 206 (46.8%) demonstrated a cam lesion. Additional baseline characteristics are summarized in Table I.

Univariate analyses revealed that the passive internal rotation ROM with the hip in a neutral flexion/extension position and with the hip in 90° of flexion were maximized in patients with femoral anteversion and decreased significantly with each

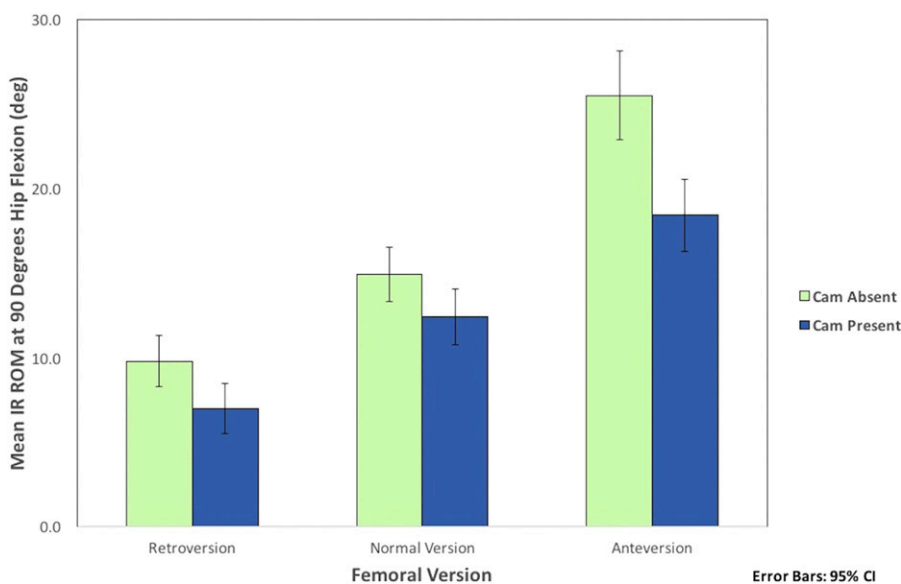


Fig. 3

Effect of femoral version and a cam lesion on passive internal rotation (IR) ROM at 90° of hip flexion.

incremental decrease in femoral version ( $p < 0.001$ ; Table II and Fig. 3). When evaluating all groups according to the degree of femoral version, the presence or absence of a cam lesion did not significantly alter passive hip rotational ROM. However, in hips with femoral anteversion, internal rotation significantly decreased in the presence of cam impingement. This effect was not observed in hips with normal femoral version or femoral retroversion.

Multivariate linear regression analysis confirmed that femoral version was the stronger independent predictor of internal rotation ROM at  $90^\circ$  of hip flexion ( $\beta = 0.45$ , 95% CI = 0.30 to 0.59,  $t = 5.83$ ,  $p < 0.001$ ). The presence of a cam lesion did not significantly increase the predictive value of the model ( $p = 0.394$ ). The effect of femoral version on internal rotation ROM at  $90^\circ$  of hip flexion was independent of which hip (right or left) was measured ( $F = 0.074$ , numerator degrees of freedom [ndf] = 1, denominator degrees of freedom [ddf] = 218.553,  $p = 0.074$ ). The final predictive model is: hip internal rotation ROM at  $90^\circ$  of hip flexion =  $5.36 + (\text{femoral version} \times 0.45)$ .

In contrast, passive hip flexion ROM was significantly decreased in hips with a cam lesion compared with those without one ( $p < 0.001$ ; Table II), and there were no additional effects due to the degree of femoral version (Table II).

## Discussion

In this prospective analysis of 440 hips, the most important finding was that abnormalities of femoral version significantly outweigh the effects of a cam lesion on hip internal rotation ROM. However, in hips with femoral anteversion, cam impingement significantly decreased internal rotation ROM. These results demonstrate the importance of evaluating the overall hip anatomy, including femoral version, in patients presenting with symptoms of impingement.

Previous studies have examined the combined effects of different hip morphologic features on ROM. In a cohort study of 30 patients (10 healthy controls, 10 patients with asymptomatic FAI, and 10 with symptomatic FAI), Audenaert et al.<sup>9</sup> found that cam size, acetabular coverage, and femoral version predicted hip internal rotation. In another study, passive hip ROM was shown to predict femoral and acetabular version<sup>21</sup>. In a consecutive cohort of 221 patients (442 hips) who underwent hip arthroscopy, Chadayammuri et al.<sup>21</sup> found that hips with femoral and acetabular anteversion exhibited the greatest internal rotation (mean,  $44.2^\circ$ ) at a neutral hip flexion/extension position, whereas hips with femoral and acetabular retroversion had the least internal rotation (mean,  $20.1^\circ$ ;  $p < 0.001$ ).

Cam-type FAI results from a nonspherical extension of the femoral head causing impingement against the spherical acetabular cavity<sup>4</sup>. Patients with a cam lesion often have pain and a reduced hip ROM, specifically internal rotation<sup>5-8</sup>. Traditionally, surgical treatment of FAI required surgical hip dislocation<sup>23,24</sup>. In recent years, arthroscopic treatment of FAI has become the norm, with a number of studies showing successful outcomes in terms of reduced pain levels, improved function, and return to sports<sup>25-30</sup>.

In addition to successful pain relief and improvements in functional outcomes, hip arthroscopy for patients with cam-type FAI has been shown to result in significant increases in ROM

postoperatively<sup>30,31</sup>. In a series of 22 patients, Stähelin et al.<sup>30</sup> found that, on average, hip internal rotation increased from  $5^\circ$  preoperatively to  $22^\circ$  at 6 months postoperatively and hip flexion increased from  $107^\circ$  to  $124^\circ$ . In a cohort of 55 patients (56 hips) who underwent arthroscopic decompression of a cam lesion, Kelly et al.<sup>31</sup> found that internal rotation increased, on average, from  $9.9^\circ$  preoperatively to  $27.6^\circ$  immediately postoperatively and  $30.1^\circ$  at 3 months postoperatively ( $p < 0.001$ ). Hip flexion also significantly increased, from  $115.7^\circ$  preoperatively to  $127.9^\circ$  at 3 months ( $p < 0.003$ )<sup>31</sup>. However, the degree of internal rotation improvement correlated with femoral version, with patients with increased anteversion experiencing greater internal rotation postoperatively (mean,  $34.3^\circ$ ) compared with those with relative retroversion (mean,  $25.2^\circ$ ;  $p < 0.05$ ).

Femoral version also affects the postoperative subjective outcomes of hip arthroscopy for cam-type FAI. In a prospective cohort study in which 243 patients were evaluated at a mean of 21 months after hip arthroscopy for FAI, Fabricant et al.<sup>32</sup> observed overall significant improvements in the modified Harris Hip Score (mHHS), the Hip Outcome Score (HOS) Activities of Daily Living (ADL) and Sports subscale scores, and the International Hip Outcome Tool (iHOT-33) scores. However, the postoperative improvements in patients with relative femoral retroversion ( $<5^\circ$  of anteversion) were of significantly smaller magnitude than those in patients with normal or increased version. Thus, the findings of this study highlight the importance of evaluating femoral version in patients with cam-type FAI.

When a patient presents with symptoms of hip impingement, the surgeon should evaluate the overall anatomy of the hip, as hip impingement is a multifactorial diagnosis that may occur as a result of a combination of cam-type FAI, abnormal femoral version, acetabular version, and/or acetabular osseous coverage. When a patient has femoral retroversion, the surgeon may consider offering procedures such as a derotational femoral osteotomy in place of, or in addition to, arthroscopic management of cam lesions. Future studies should be performed to compare the effects of cam resection, derotational femoral osteotomy, and a combination of these procedures on improvements in hip ROM, pain, and functional activities.

The strengths of this study include the prospective collection of data from a large sample of hips and blinding of the evaluators of the ROM to the imaging results. The limitations of this study should also be noted. First, the applicability of our findings may be limited to normal hips and hips undergoing treatment for relatively mild anatomic deformity of the proximal aspect of the femur and/or the acetabulum. Patients with more substantial pathologic involvement and deformities such as SCFE or Legg-Calvé-Perthes disease, who were excluded from this study, may demonstrate trends that are different from those reported in the present study. Additionally, we did not assess the effects of anterior acetabular coverage, acetabular retroversion, or subspine impingement on passive hip ROM. Passive hip ROM is the product of several anatomic factors, including features such as hip capsular laxity and soft-tissue stiffness, which were not incorporated into this study. However, a prior study demonstrated that examination under anesthesia correlated well with clinical

examination, indicating that pain and guarding were not limitations of the clinical assessment of ROM<sup>33</sup>.

In conclusion, abnormalities of femoral version significantly outweigh the effect of cam-type impingement on passive hip internal rotation ROM. In contrast, cam-type impingement significantly decreases hip flexion ROM, irrespective of the degree of femoral version. These findings help to inform surgical decision-making for patients with cam-type FAI or femoral version abnormalities. ■

Matthew J. Kraeutler, MD<sup>1</sup>  
Vivek Chadayammuri, MD<sup>2</sup>

Tigran Garabekyan, MD<sup>3</sup>  
Omer Mei-Dan, MD<sup>4</sup>

<sup>1</sup>Department of Orthopaedics, Seton Hall-Hackensack Meridian School of Medicine, South Orange, New Jersey

<sup>2</sup>Department of Orthopaedic Surgery, University of Connecticut, Farmington, Connecticut

<sup>3</sup>Southern California Hip Institute, North Hollywood, California

<sup>4</sup>Department of Orthopedics, University of Colorado School of Medicine, Aurora, Colorado

E-mail address for O. Mei-Dan: omer.meidan@ucdenver.edu

ORCID iD for O. Mei-Dan: [0000-0001-7555-986X](https://orcid.org/0000-0001-7555-986X)

## References

- de Silva V, Swain M, Broderick C, McKay D. Does high level youth sports participation increase the risk of femoroacetabular impingement? A review of the current literature. *Pediatr Rheumatol Online J*. 2016 Mar 11;14(1):16.
- Lee WY, Kang C, Hwang DS, Jeon JH, Zheng L. Descriptive epidemiology of symptomatic femoroacetabular impingement in young athlete: single center study. *Hip Pelvis*. 2016 Mar;28(1):29-34. Epub 2016 Mar 31.
- Packer JD, Safran MR. The etiology of primary femoroacetabular impingement: genetics or acquired deformity? *J Hip Preserv Surg*. 2015 Jun 18;2(3):249-57.
- Ganz R, Leunig M, Leunig-Ganz K, Harris WH. The etiology of osteoarthritis of the hip: an integrated mechanical concept. *Clin Orthop Relat Res*. 2008 Feb;466(2):264-72.
- Bagwell JJ, Snibbe J, Gerhardt M, Powers CM. Hip kinematics and kinetics in persons with and without cam femoroacetabular impingement during a deep squat task. *Clin Biomech (Bristol, Avon)*. 2016 Jan;31:87-92.
- Diamond LE, Wrigley TV, Bennell KL, Hinman RS, O'Donnell J, Hodges PW. Hip joint biomechanics during gait in people with and without symptomatic femoroacetabular impingement. *Gait Posture*. 2016 Jan;43:198-203.
- Kapron AL, Anderson AE, Peters CL, Phillips LG, Stoddard GJ, Petron DJ, Toth R, Aoki SK. Hip internal rotation is correlated to radiographic findings of cam femoroacetabular impingement in collegiate football players. *Arthroscopy*. 2012 Nov;28(11):1661-70.
- Yuan BJ, Bartelt RB, Levy BA, Bond JR, Trousdale RT, Sierra RJ. Decreased range of motion is associated with structural hip deformity in asymptomatic adolescent athletes. *Am J Sports Med*. 2013 Jul;41(7):1519-25.
- Audenaert EA, Peeters I, Vigneron L, Baelde N, Pattyn C. Hip morphological characteristics and range of internal rotation in femoroacetabular impingement. *Am J Sports Med*. 2012 Jun;40(6):1329-36.
- Mei-Dan O, McConkey MO, Knudsen JS, Brick MJ. Bilateral hip arthroscopy under the same anesthetic for patients with symptomatic bilateral femoroacetabular impingement: 1-year outcomes. *Arthroscopy*. 2014 Jan;30(1):47-54.
- Martin HD, Kelly BT, Leunig M, Philippon MJ, Clohisy JC, Martin RL, Sekiya JK, Pietrobon R, Mohtadi NG, Sampson TG, Safran MR. The pattern and technique in the clinical evaluation of the adult hip: the common physical examination tests of hip specialists. *Arthroscopy*. 2010 Feb;26(2):161-72.
- Clohisy JC, Carlisle JC, Beaulé PE, Kim YJ, Trousdale RT, Sierra RJ, Leunig M, Schoenecker PL, Millis MB. A systematic approach to the plain radiographic evaluation of the young adult hip. *J Bone Joint Surg Am*. 2008 Nov;90(Suppl 4):47-66.
- Delaunay S, Dussault RG, Kaplan PA, Alford BA. Radiographic measurements of dysplastic adult hips. *Skeletal Radiol*. 1997 Feb;26(2):75-81.
- Weber AE, Jacobson JA, Bedi A. A review of imaging modalities for the hip. *Curr Rev Musculoskelet Med*. 2013 Sep;6(3):226-34.
- Jesse MK, Petersen B, Strickland C, Mei-Dan O. Normal anatomy and imaging of the hip: emphasis on impingement assessment. *Semin Musculoskelet Radiol*. 2013 Jul;17(3):229-47.
- Mose K. Methods of measuring in Legg-Calvé-Perthes disease with special regard to the prognosis. *Clin Orthop Relat Res*. 1980 Jul-Aug;150:103-9.
- Ogata S, Moriya H, Tsuchiya K, Akita T, Kamegaya M, Someya M. Acetabular cover in congenital dislocation of the hip. *J Bone Joint Surg Br*. 1990 Mar;72(2):190-6.
- Kraeutler MJ, Garabekyan T, Pascual-Garrido C, Mei-Dan O. Hip instability: a review of hip dysplasia and other contributing factors. *Muscles Ligaments Tendons J*. 2016 Dec 21;6(3):343-53.
- Tannast M, Siebenrock KA, Anderson SE. Femoroacetabular impingement: radiographic diagnosis—what the radiologist should know. *AJR Am J Roentgenol*. 2007 Jun;188(6):1540-52.
- Clohisy JC, Knaus ER, Hunt DM, Leshner JM, Harris-Hayes M, Prather H. Clinical presentation of patients with symptomatic anterior hip impingement. *Clin Orthop Relat Res*. 2009 Mar;467(3):638-44.
- Chadayammuri V, Garabekyan T, Bedi A, Pascual-Garrido C, Rhodes J, O'Hara J, Mei-Dan O. Passive hip range of motion predicts femoral torsion and acetabular version. *J Bone Joint Surg Am*. 2016 Jan 20;98(2):127-34.
- Landis JR, Koch GG. The measurement of observer agreement for categorical data. *Biometrics*. 1977 Mar;33(1):159-74.
- Naal FD, Miozzari HH, Wyss TF, Nötzli HP. Surgical hip dislocation for the treatment of femoroacetabular impingement in high-level athletes. *Am J Sports Med*. 2011 Mar;39(3):544-50.
- Peters CL, Schabel K, Anderson L, Erickson J. Open treatment of femoroacetabular impingement is associated with clinical improvement and low complication rate at short-term followup. *Clin Orthop Relat Res*. 2010 Feb;468(2):504-10.
- Kierkegaard S, Langeskov-Christensen M, Lund B, Naal FD, Mechenburg I, Dalgas U, Casartelli NC. Pain, activities of daily living and sport function at different time points after hip arthroscopy in patients with femoroacetabular impingement: a systematic review with meta-analysis. *Br J Sports Med*. 2017 Apr;51(7):572-9.
- Larson CM, Giveans MR. Arthroscopic management of femoroacetabular impingement: early outcomes measures. *Arthroscopy*. 2008 May;24(5):540-6
- Lee S, Frank RM, Harris J, Song SH, Bush-Joseph CA, Salata MJ, Nho SJ. Evaluation of sexual function before and after hip arthroscopic surgery for symptomatic femoroacetabular impingement. *Am J Sports Med*. 2015 Aug;43(8):1850-6.
- Lee S, Kuhn A, Draovitch P, Bedi A. Return to play following hip arthroscopy. *Clin Sports Med*. 2016 Oct;35(4):637-54.
- Levy DM, Kuhns BD, Frank RM, Grzybowski JS, Campbell KA, Brown S, Nho SJ. High rate of return to running for athletes after hip arthroscopy for the treatment of femoroacetabular impingement and capsular plication. *Am J Sports Med*. 2017 Jan;45(1):127-34.
- Stähelin L, Stähelin T, Jolles BM, Herzog RF. Arthroscopic offset restoration in femoroacetabular cam impingement: accuracy and early clinical outcome. *Arthroscopy*. 2008 Jan;24(1):51-57.e1.
- Kelly BT, Bedi A, Robertson CM, Dela Torre K, Giveans MR, Larson CM. Alterations in internal rotation and alpha angles are associated with arthroscopic cam decompression in the hip. *Am J Sports Med*. 2012 May;40(5):1107-12.
- Fabricant PD, Fields KG, Taylor SA, Magennis E, Bedi A, Kelly BT. The effect of femoral and acetabular version on clinical outcomes after arthroscopic femoroacetabular impingement surgery. *J Bone Joint Surg Am*. 2015 Apr 1;97(7):537-43.
- Chadayammuri V, Pascual-Garrido C, Garabekyan T, Kraeutler MJ, Milligan K, Bedi A, Mei-Dan O. Effect of general anesthesia on preoperative hip range of motion in patients undergoing hip arthroscopy. *Orthopedics*. 2016 Nov 1;39(6):e1165-9. Epub 2016 Aug 18.