

Hip Distraction Without a Perineal Post

A Prospective Study of 1000 Hip Arthroscopy Cases

Omer Mei-Dan,^{*†} MD, Matthew J. Kraeutler,[‡] MD, Tigran Garabekyan,[§] MD,
Jesse A. Goodrich,^{||} BA, and David A. Young,[¶] MBBS, FRACS (Orth)

Investigation performed at CU Sports Medicine and Performance Center,

Department of Orthopedics, University of Colorado School of Medicine, Boulder, Colorado, USA

Background: Hip arthroscopy has traditionally been performed with a perineal post, resulting in various groin-related complications, including pudendal nerve neurapraxias, vaginal tears, and scrotal necrosis.

Purpose: To assess the safety of a technique for hip distraction without the use of a perineal post.

Study Design: Case series; Level of evidence, 4.

Methods: We prospectively analyzed a consecutive cohort of 1000 hips presenting to a dedicated hip preservation clinic; all patients had hip pain and were subsequently treated with hip arthroscopy. Demographic variables, hip pathology, and lateral center edge angle were recorded for each case. In the operating room, the patient's feet were placed in traction boots in a specifically designed distraction setup, and the operative table was placed in varying degrees of Trendelenburg. With this technique, enough resistance is created by gravity and friction between the patient's body and the bed to allow for successful hip distraction without the need for a perineal post. In a subset of 309 hips ($n = 281$ patients), the degrees of Trendelenburg as well as the distraction force were analyzed.

Results: The mean \pm SD Trendelenburg angle used among the subset of 309 hips was $11^\circ \pm 2^\circ$. The mean initial distraction force necessary was 90 ± 28 lb, which decreased to 65 ± 24 lb by 30 minutes after traction initiation ($P < .0001$). The most important variables in determining initial force for this cohort of patients were, in order of magnitude, sex ($P < .0001$), weight ($P < .0001$), and lateral center edge angle ($P < .01$). No groin-related complications occurred among the entire cohort of patients, including soft tissue or nerve-related complications. The rate of deep venous thrombosis was 2 in 1000.

Conclusion: The use of the Trendelenburg position and a specially designed distraction setup during hip arthroscopy allows for safe hip distraction without a perineal post, thereby eliminating groin-related soft tissue and nerve complications. Certain patient variables can be used to estimate the required distraction force and inclination angle with this method.

Keywords: complications; hip arthroscopy; hip distraction; perineal post; pudendal neurapraxia

Hip arthroscopy has gained significant popularity within the last decade, with an incidence increasing $>250\%$ from 2007 to 2011.³⁸ Glick et al¹⁶ first reported on the use of hip arthroscopy via the lateral approach in 1987, with Byrd² describing the use of the supine position with hip arthroscopy in 1994. Because the hip is a highly constrained joint with a thick soft tissue envelope, distraction of the joint is necessary to visualize the central compartment.⁸ To gain access to the hip joint during arthroscopy, a designated traction table is used with a perineal post to enable countertraction and maintain hip distraction. A traction force of 89 to 127 lb may be necessary to sufficiently distract the joint in anesthetized patients.⁴⁰

The perineal post results in high force vectors against the patient's groin (Figure 1). Consequently, 2 types of traction complications have been reported directly relating to the perineal post: pressure-related soft tissue damage to the perineum and compression-related neurapraxias and permanent injury to the pudendal and other surrounding nerves.^{15,22,30,32} Clinical symptoms of neurapraxias of the pudendal nerve include perineal pain and hypoesthesia or anesthesia of the glans penis and scrotum in men and the perineum and labia in women. This may be associated with sexual disorders, including erectile and ejaculatory disturbances and hypo-orgasmia. These complications are typically transient and resolve within days, weeks, or months,³⁵ although permanent damage related to the use of a perineal post has been documented.²⁰ In addition to neurapraxias, the use of a perineal post during hip arthroscopy has been associated with soft tissue complications, including scrotal³⁹ and labial necrosis¹⁵ as well as vaginal tears.^{8,17}

The purpose of this study was to prospectively assess the safety of a postless technique for hip distraction during

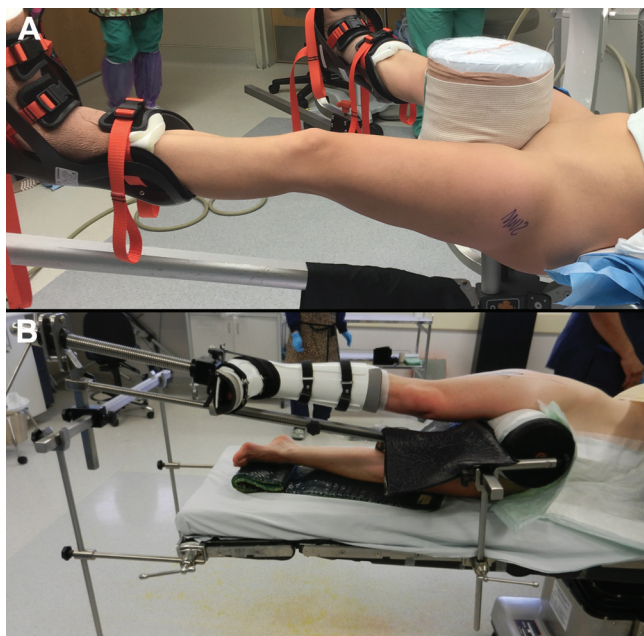


Figure 1. Intraoperative photograph demonstrating (A) supine and (B) lateral positioning for hip distraction utilizing a 10-inch perineal post. Both techniques achieve hip distraction by applying countertraction to the perineum.

hip arthroscopy. We hypothesized that this technique would eliminate perineal complications while enabling adequate distraction to allow safe access and maneuverability within the joint.

METHODS

Surgical Technique

General anesthesia was used. No nerve blocks, spinal anesthesia, or complete muscle paralysis was utilized. The patient was placed in a supine position on a traction table on top of a sheet with a commercially available shape-conforming foam (The Pink Pad; Xodus Medical Inc) to generate friction between the patient's body and table and to protect the patient from nerve damage and pressure ulcers (see Video Supplement, available in the online version of this article). Only the patient's buttock and lower back were in contact with the table. The upper limbs were tied together on the patient's torso. No straps were used to fix the patient to the

TABLE 1
Patient Characteristics That Allow
for Easy vs Difficult Hip Distraction^a

Easy Distraction	Difficult Distraction
Females with joint laxity	Older males with hip OA and joint stiffness
Higher BMI (>30 kg/m ²)	Young thin males
Hip dysplasia ²³	Large cam lesions

^aBased on the senior author's experience performing hip arthroscopy without a perineal post in approximately 1200 total cases. Joint laxity is based on the Beighton Hypermobility Score: 0-2 points, no laxity; 3-5, mild laxity; 6-9, moderate/severe laxity. BMI, body mass index; OA, osteoarthritis.

bed. Bony prominences of the foot and ankle were padded, and traction was achieved with the use of a limb positioner affixed to custom-machined table attachment arms enabling unrestricted limb positioning for optimal maneuverability and access during the procedure (Figure 2). The operative table was placed in approximately 5° to 15° of Trendelenburg based on the patient's sex, pathology, body habitus, and weight (Table 1). The limb was adjusted after Trendelenburg was established to ensure that the operative limb was positioned in 0° to 5° of flexion and abduction relative to the pelvis. Fifteen degrees of hip internal rotation was applied (measured at the foot), bringing the femoral neck in profile and allowing for optimal portal placement. The nonoperative limb was placed in 30° to 40° of abduction based on examination under anesthesia values for abduction range of motion, slight flexion (0°-5°), and gravity external rotation. This allowed space for the fluoroscopy unit to obtain lateral images of the hip while maintaining no stress on the nonoperative limb (Figure 2). With this technique and the patient in 5° to 15° of Trendelenburg, enough resistance was created by gravity and friction between the patient's body and the operating table to act as counterforce and prevent caudal translation of the body.

When positioning was complete, the leg was prepared in a standard sterile fashion for hip arthroscopy. A needle was inserted anteriorly and directed to the femoral neck to vent the joint with 20 to 30 mL of air and break the suction seal.²⁷ This enabled lower subsequent traction forces to be used in achieving adequate distraction of the hip.¹⁰ Traction was gradually applied on the operative limb with the goal of achieving >10 mm of lateral distraction (between the lateral rim and the femoral head) to enable safe introduction of instrumentation. Both gross and fine

*Address correspondence to Omer Mei-Dan, MD, University of Colorado School of Medicine, 12631 East 17th Avenue, Mail Stop B202, Room L15-4505, Aurora, CO 80045, USA (email: omer.meidan@ucdenver.edu).

[†]Department of Orthopedics, University of Colorado School of Medicine, Aurora, Colorado, USA.

[‡]Department of Orthopaedics, Seton Hall-Hackensack Meridian School of Medicine, South Orange, New Jersey, USA.

[§]Southern California Hip Institute, North Hollywood, California, USA.

^{||}Department of Integrative Physiology, University of Colorado Boulder, Boulder, Colorado, USA.

[¶]Melbourne Orthopaedic Group, Melbourne, Australia.

One or more of the authors has declared the following potential conflict of interest or source of funding: O.M.-D. has shares in a company (MITA) that sold the rights and patents for the bed/technique described in this study and gains financially from its commercialization. As a part of the transaction, O.M.-D. may receive royalties from Stryker based on the commercialization of this distraction construct. O.M.-D. is also a consultant for Stryker (related and unrelated to this study). T.G. is a consultant for Stryker (related and unrelated to this study).

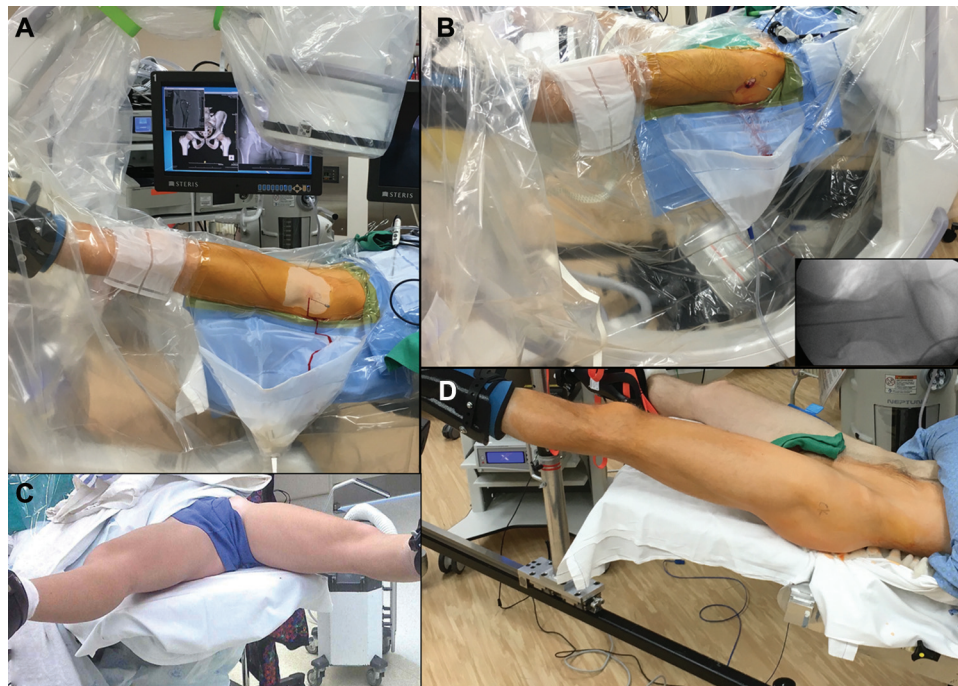

Figure 2. (A) Intraoperative photograph demonstrating technique for obtaining an anteroposterior fluoroscopic view by arcing the fluoroscope to maintain an orthogonal beam trajectory to the patient in Trendelenburg. (B) A cross-table lateral hip fluoroscopic view can be obtained by positioning the fluoroscope between the patient's legs, with good visualization attributed to the absence of the perineal post. The fluoroscopic image demonstrates central placement of the 17-gauge, 6-inch needle utilized to percutaneously establish the midtrochanteric portal. (C, D) Intraoperative photographs of the postless technique showing no pressure on the perineum during application of traction.

traction techniques were used. The peak traction force was measured at this stage, seconds after application of traction and just before establishing the first portal just proximal and anterior to the tip of the greater trochanter. A standard anterolateral portal was then established under biplanar fluoroscopic visualization.²⁶

While addressing central compartment pathology (Figure 3), the surgeon was free to release traction, if desired, to improve visualization of the capsulolabral recess or permit dynamic impingement evaluation before acetabuloplasty. Intermittent release and reapplication of traction were performed as needed throughout the procedure. Upon completion of central compartment work, traction was released, the bed was repositioned to a neutral tilt, and the central bootstrap was unlocked to prevent compression injury around the foot and ankle.

Trendelenburg angle was recorded separately with 2 “Level” apps (Figure 4) after calibration before each use. Some surgical beds had an internal “Level” indicator on their remote control, and this was matched with the app results. Traction forces were measured via a specifically designed load cell device (Transducer Techniques; Figure 4).

Postoperative Rehabilitation and Evaluation

No bracing was used postoperatively. Patients were advised to limit hip flexion to 90° and avoid forced external rotation for 3 weeks to minimize stress against the

capsular repair. Gentle stationary bicycling was initiated on postoperative day 1. All patients were encouraged to bear weight as tolerated on both hips, utilizing crutches for balance and support during the first 10 to 14 days postoperatively, unless microfracture was performed, in which case 6 weeks of nonweightbearing was prescribed. Deep venous thrombosis prophylaxis was not used. Naproxen, 500 mg twice per day for 25 days, was prescribed in cases of large cam or pincer bony resection for prophylaxis against heterotopic ossification.

All patients were seen and examined by the operating surgeon in the postanesthesia care unit 30 to 120 minutes postoperatively and then at 10 to 14 days postoperatively, where a physical examination was performed and specific questions related to procedure side effects and complications were asked and documented. This included a full neurovascular examination and questions regarding the location of any postoperative pain. Additionally, all patients were followed at 6 weeks, 3 and 6 months, and 1 and 2 years.

Study Population

Following Institutional Review Board approval, we prospectively analyzed a consecutive cohort of 1000 hips presenting to a dedicated hip preservation clinic and undergoing hip arthroscopy by the senior author (O.M.-D.) from 2012 to 2016. Patient demographics, physical examination, imaging modalities, diagnoses, surgical procedure, and follow-up

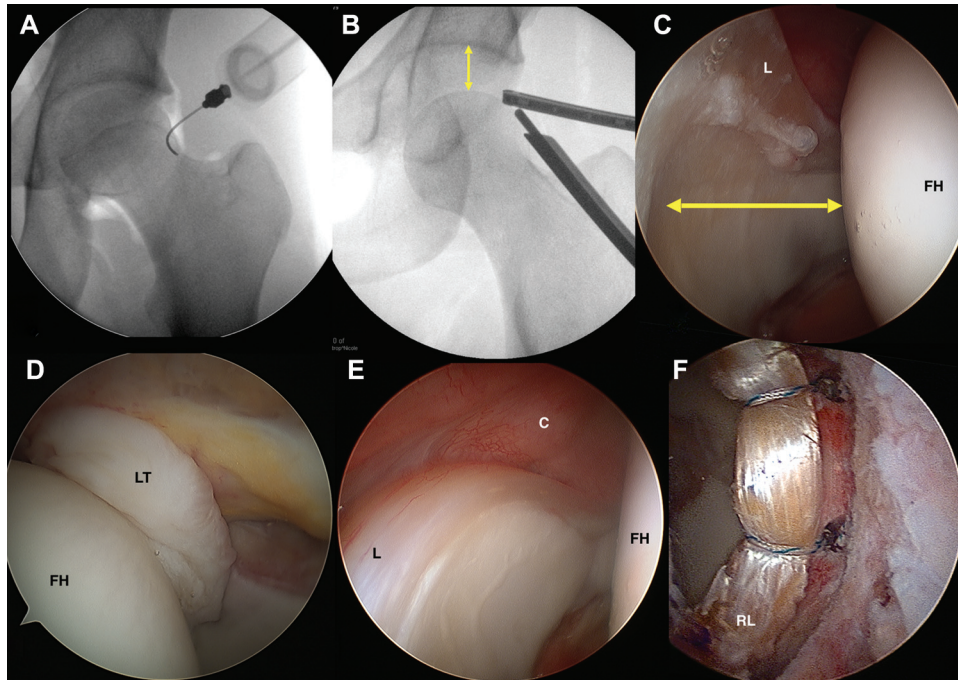


Figure 3. (A) Anteroposterior fluoroscopic image of a left hip before the application of traction with a 17-gauge, 6-inch needle placed intracapsularly at the level of the femoral head-neck junction to perform an air arthrogram. Air can be seen outlining the labrum laterally and demarcating the level of the zona orbicularis. (B) Gentle application of traction is performed after venting the joint with an air arthrogram, achieving the desired degree of distraction within the hip joint (arrows), as demonstrated in this posttraction anteroposterior fluoroscopic view of the left hip. (C) Arthroscopic view of a right hip with a 30° arthroscope placed in the midtrochanteric portal (the senior author's version of the anterolateral portal) visualizing the femoral head (FH) to the right, the acetabulum and labrum (L) to the left, and adequate space for instrumentation in between (arrows). (D) Arthroscopic view of a left hip with a 70° arthroscope inserted through the midanterior portal deep into the central compartment to visualize the cotyloid fossa, ligamentum teres (LT), and inferomedial femoral head. (E) Arthroscopic view of a right hip with a 30° arthroscope inserted through the midtrochanteric portal visualizing the anterosuperior labrum, anterior capsule (C), and femoral head, or the so-called anterior triangle, before establishing the midanterior portal under direct visualization. (F) Arthroscopic view of a left hip with the 30° arthroscope placed through the midtrochanteric portal after a labral reconstruction showing the acetabular rim and well-positioned reconstructed labral (RL) graft. All intraoperative visualization was achievable with postless distraction.

visit data were collected prospectively. The primary outcome measure was groin-related complications in the overall cohort. For a consecutive cohort of 309 hips ($n = 281$ patients) of the overall 1000 hips in this cohort, the degrees of Trendelenburg and the distraction force initially and at 5, 10, 20, and 30 minutes after initiation were prospectively recorded. Common indications for referral included femoroacetabular impingement, hip instability,²³ acetabular dysplasia, and associated abnormalities of femoral torsion or acetabular version. Demographic variables, including age, sex, height, weight, and body mass index, were recorded for all patients. Hip pathology and lateral center edge angle (LCEA) were also recorded for each patient.

Statistical Analysis

To determine how traction force changed over time, a linear mixed model was used, with the independent variable as the log transformation of time. To determine significant predictors of traction force, linear mixed model analysis was performed. In all analyses, Trendelenburg angle was included

as a covariate. For all mixed models, normality of residuals were assessed with Q-Q and residuals plots, and multicollinearity was tested with variance inflation factors. Relative importance and P values for each fixed factor were calculated with a likelihood ratio test. Once predictors of distraction force were determined, descriptive statistics were calculated by splitting continuous variables at the median. A Fisher exact test was performed to determine whether there was a difference in incidence of groin-related nerve injury between the newly described technique for hip distraction and the classic approach. This test had a power of 0.99 to detect a difference in the proportion of groin-related complications. Statistical analysis was performed with R Statistical Software (R Foundation for Statistical Computing).

RESULTS

Through the duration of this study, a total of 1000 hip arthroscopies were performed (Table 2), and no groin-related soft tissue or nerve complications were documented.

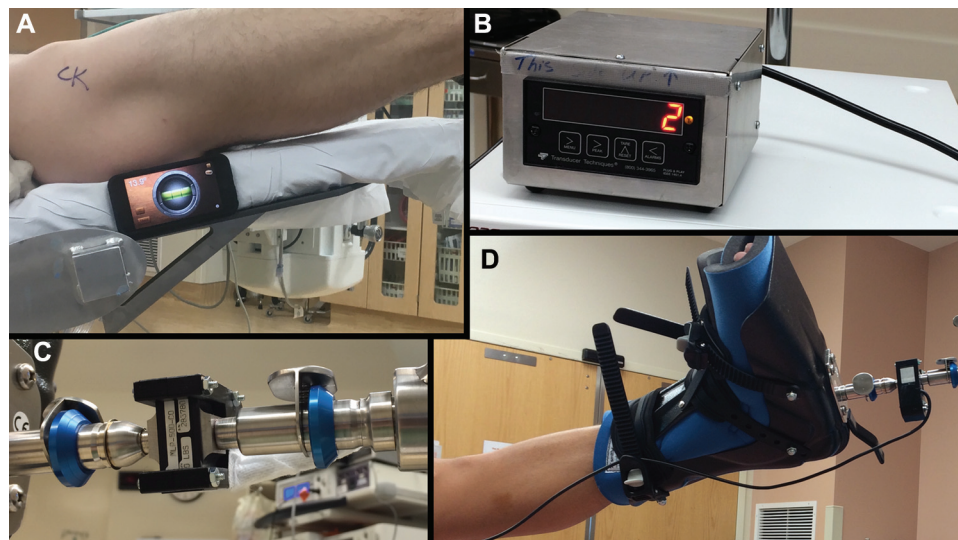


Figure 4. Intraoperative photographs showing (A) the use of a smartphone application to measure the degrees of Trendelenburg tilt on the operative bed before the application of traction; (B) the pressure transducer reading for measuring traction force throughout the procedure; and (C) the locking mechanism for the traction boot and the spider device as well as (D) the positioning of the limb in the traction boot.

Follow-up at 2 years postoperatively included 630 hips and another 270 at a minimum of 1 year after surgery. Furthermore, no complications (friction burns, skin contusions) were documented as a result of the necessary friction created between the patient's body and the operating table. Traction time averaged 61 minutes (range, 22-111 minutes) for femoroacetabular impingement/labral repair cases. However, some unique cases, such as ligamentum teres reconstruction, resulted in much longer continuous traction time (up to 140 minutes). In labral reconstruction cases, the initial traction was released after 15 to 40 minutes (at the conclusion of acetabular rim preparation), at which time the cam lesion was addressed while the graft was prepared. Traction was then reapplied for graft implementation with a mean additional traction time of 55 minutes.

The mean \pm SD angle of Trendelenburg used among the subset of patients was $11^\circ \pm 2^\circ$, and the mean initial distraction force necessary was 90 ± 28 lb, which decreased precipitously over time ($P < .0001$), resulting in a force of 65 ± 24 lb at 30 minutes after traction was initiated (Figure 5). Although, on average, female patients started at a lower force than males, males had a significantly faster rate of decline in traction force over the 30 minutes that force was measured ($P < .001$) (Figure 5). This resulted in males experiencing a greater drop in force over the 30 minutes than females, although the necessary distraction force remained higher for males throughout the measurement period owing to the generally higher joint laxity among females.

We additionally determined which factors were most significant in determining the magnitude of traction force required to achieve adequate distraction of the hip. Patient characteristics that significantly influenced initial traction force—measured immediately after generation of adequate hip distraction—were, in order of magnitude, sex ($P < .0001$), patient weight ($P < .0001$) (Figure 6), and LCEA

TABLE 2
Hip Arthroscopy Diagnoses and Procedures Performed Under Hip Distraction Without a Perineal Post^a

Diagnosis/Procedure	No.
FAI type	
Cam	452
Pincer	137
Mixed	261
Hip dysplasia before osteotomy procedure	131
Labral	
Repair	827
Reconstruction	93
Debridement	41
Microfracture	213
Bone grafting of subchondral cysts	28
Iliopsoas release	27
Miscellaneous ^b	24

^aMore than 1 procedure was performed at a time in most cases. FAI, femoroacetabular impingement.

^bPostdislocation, ligamentum teres reconstruction, synovial chondromatosis, diagnostic hip arthroscopy.

($P < .01$) (Figure 7, Table 3). These 3 predictors accounted for 49% of the variability in initial distraction force. According to the results from the final linear mixed model, males in this cohort required a mean 27 lb of greater initial force than females ($P < .01$). For every 1-lb increase in patient weight, there was a corresponding 0.29-lb increase in traction force ($P < .01$). For every 1° increase in LCEA, the traction force required increased by 0.59 lb ($P < .001$).

At the 30-minute time point, after establishment of 2 surgical portals and performance of an interportal capsulotomy, traction forces were significantly lower. However, the 3

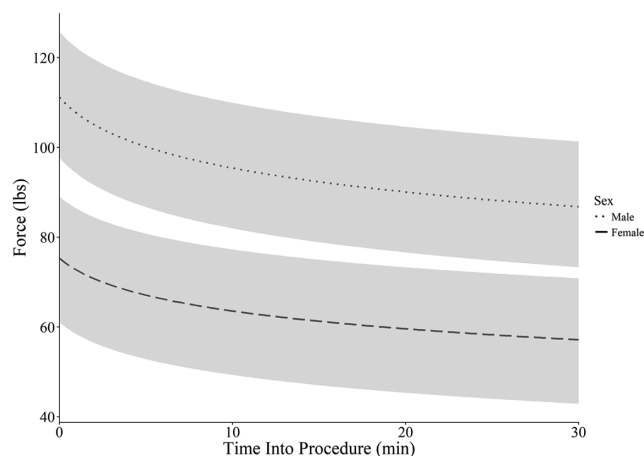


Figure 5. Changes in force over time in males versus females. The darker lines represent the predicted change in force after initiation of traction based on sex. The shaded portion indicates the region containing 50% of all patients, by sex. Males required a significantly higher traction force than females throughout the entire 30 minutes, initially requiring 27 lb of more force ($P < .001$). However, males displayed a faster rate of decay than females ($P < .001$), resulting in a difference of only 19 lb of force 30 minutes after initiation of force.

variables that predicted force (sex, weight, and LCEA) were still significant predictors and carried the same relationship to traction force. Sex, weight, and LCEA collectively explained 45% of the variability in traction force at 30 minutes.

Of the 1000 hips in the operative cohort, only 4 ($n = 2$ patients) were undistractable. Both patients were among the first 100 patients operated on with this distraction technique, and the distraction achieved with each patient was <11 mm, which was considered by the senior author as the minimal distance required to conduct safe entry into the central compartment. After failed hip distraction, an attempt was made to try the common perineal post technique (Hip Positioning System; Smith & Nephew, Inc), although this was also unsuccessful. Both patients underwent staged hip arthroscopy with hip distraction attempted in both hips. In these cases, introduction into the joint was then performed in an outside-in manner (peripheral compartment first). Of note, even after complete capsulotomy (interportal and "T"), the space obtained between the femoral head and acetabulum upon distraction was <5 mm, as seen with fluoroscopy. With the exception of these 2 patients, all patients exhibited adequate distraction of the hip (11-20 mm) permitting procedures such as labral repair, ligamentum teres debridement, acetabular or medial femoral head microfracture, and labral reconstruction to be performed. Labral reconstruction was performed for 93 hips, and simple labral base debridement was performed for 41 hips where the labrum was found to be stable with minimal reactive tissue at the chondrolabral junction. Labral repair was performed for the remaining cases. Labral penetration (minimal, clinically insignificant) and superficial femoral

TABLE 3
Mean Initial Force and Trendelenburg Inclination Angle by Sex and Patient Body Weight^a

	Patient Body Weight	
	≥ 150 lb	<150 lb
Force, lb		
Male	120.4 ± 29.7 (118.0)	110.0 ± 18.4 (110.0)
Female	89.5 ± 24.2 (89.0)	76.2 ± 17.0 (75.0)
Inclination, deg		
Male	11.9 ± 2.6 (12.0)	11.7 ± 2.5 (11.0)
Female	10.5 ± 1.9 (10.5)	10.8 ± 2.4 (11.0)

^aMean force and Trendelenburg angle were calculated on the basis of patient sex and body weight divided at the median. Data are reported as a mean \pm SD (median).

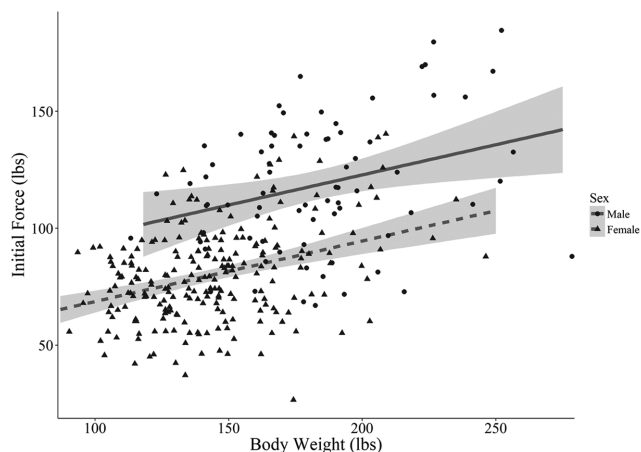


Figure 6. Influence of body weight on initial force based on sex. This graph also shows the distribution of body weight and initial force for the entire cohort.

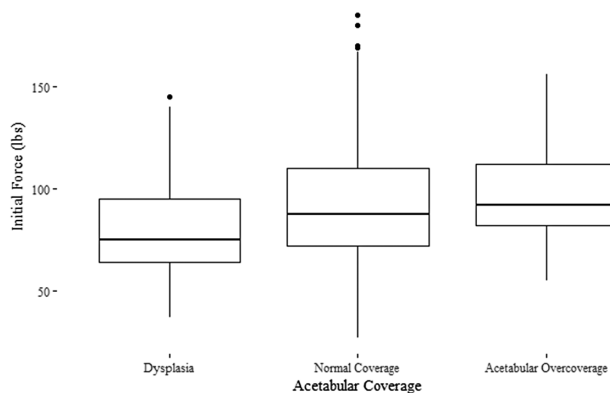


Figure 7. Relationship between acetabular coverage and initial force, without taking into account any other variables. Acetabular coverage was determined by lateral center edge angle. Values are presented as box and whisker plots, in lbs of force. $*P < .05$.

head iatrogenic cartilage injury occurred in 35 hips of this 1000-hip cohort as a result of misplacement of the needle during establishment of the arthroscopy portals, usually in relation to a trainee's learning curve of introduction into the joint.

There were 2 cases of symptomatic deep venous thrombosis reported (2 of 1000, 0.2%). Both patients had associated risk factors (body mass index >35 kg/m², diabetes mellitus, older age). There were no cases of patients falling from the operating table during surgery.

DISCUSSION

This study reports the outcomes of a technique for hip arthroscopy without a perineal post. There were no groin-related nerve or soft tissue complications in a cohort of 1000 hip arthroscopies. If we assume a very conservative estimate of 1% as the incidence of traction-related nerve and soft tissue injuries during conventional hip distraction with a perineal post (2% in a review by Gupta et al¹⁸ and 30% in a study by Dippmann et al¹¹), the incidence of zero nerve and soft tissue injuries in this study is significantly lower ($P < .001$).

Distraction of the hip was adequate to permit safe placement of a fluoroscopically guided anterolateral portal. Furthermore, the traction force vector enabled access to the cotyloid fossa and medial aspect of the femoral head without the need for a lateralized perineal post to provide a medial buttress against the upper thigh. Mean Trendelenburg angles were moderate, nondisorienting for the surgeon, and did not have any negative effects on hemodynamics.

The pudendal nerve carries sensation to the external genitalia of both sexes as well as the motor supply to the external urethral and anal sphincters. Kocaoğlu et al²¹ recently showed in a cadaveric model that the forces acting on the pudendal nerve, especially the perineal and dorsal genital branches, increase with increasing traction from 0 to 88 lb during utilization of a perineal post. Hip abduction angle had no significant effect on pudendal nerve compression.

Pudendal nerve palsy is among the most common complications after hip arthroscopy with a perineal post.^{11,18,20,30} Countertraction force via the perineal post is clearly responsible for pudendal nerve neurapraxia during hip arthroscopy. Rudge³⁶ demonstrated that sustained pressure of 1.4 kg/cm² for 90 minutes produced a complete block of nerve conduction. The pressure exerted on the perineal region from the post during traction and central compartment work is estimated as >1.4 kg/cm².⁶

In the most recent comprehensive review of the literature, Gupta et al¹⁸ identified 81 studies reporting on 6277 operated hips among 5535 patients. They reported 285 complications for a rate of 4.5%. The most common complication was postoperative neurapraxia (104 hips), including pudendal ($n = 30$) and sciatic ($n = 23$) neurapraxias. They also reported 23 cases of soft tissue damage, including perineal skin damage ($n = 10$), labial hematoma ($n = 3$), and scrotal hematoma ($n = 1$). In total, these 2

types of perineal post-related complications accounted for 23.5% of the reported intraoperative complications.¹⁸ In a systematic review of 92 studies with 6134 patients, Harris et al²⁰ showed that, aside from iatrogenic chondral and labral injuries, pudendal nerve injuries ($n = 34$) were the most common complication after hip arthroscopy. In this same systematic review, perineal skin damage also occurred in 10 cases overall (0.16%).

Dippmann et al¹¹ reported on 50 patients who completed follow-up questionnaires focused on the rate, pattern, and severity of nerve dysfunction symptoms. Twenty-three patients (46%) reported symptoms of nerve dysfunction during the first week. This was reduced to 14 patients (28%) after 6 weeks, 11 (22%) after 26 weeks, and 9 (18%) after 1 year. Of the 23 cases of nerve dysfunction, 15 (30%) were symptomatic pudendal neurapraxias. The authors concluded that these nerve complications are probably underreported. Other authors have concurred, stating that this diagnosis is frequently overlooked and that the incidence is often underestimated.³¹ Finally, an ongoing prospective study, based on specific questionnaires, found a 25% incidence of short-term urologic or sexual dysfunction related to the use of a perineal post during hip arthroscopy (O. R. Ayeni, MD, FRCSC, personal communication, January 2017).

Numerous retrospective reports of neurapraxia (Table 4) and perineal soft tissue damage (Table 5) after hip arthroscopy have been published. Park et al³² found a 2.0% incidence of pudendal neurapraxia among 200 hip arthroscopies among patients with a mean age of 44 years. Studying 218 hip arthroscopies within an adolescent population, Nwachukwu et al³⁰ found an overall complication rate of 1.8%, with pudendal nerve palsy accounting for half these complications. In a series of 54 hip arthroscopies in adolescent patients,²² pudendal nerve palsy occurred in 3 cases (5.6%), with spontaneous resolution by 3 months in all cases. In some cases, the complications were permanent, requiring urologic surgical intervention. The senior author has performed several revision operations on patients who suffered permanent nerve damage to their sex organs during primary hip arthroscopy when a perineal post was used. In 1 case, a patient required 7 urologic operations with suboptimal aesthetic results and permanent sexual dysfunction.

Martin et al²⁴ reported on a group of 15 patients in which somatosensory evoked potentials of the posterior tibial nerve and superficial peroneal nerve were monitored intraoperatively. A mean of 57.7 lb of traction was applied for a mean of 27.3 minutes. A $>50\%$ decrease in amplitude on the operative limb was observed for 8 of 15 patients ($n = 5$, posterior tibial nerve only; $n = 1$, superficial peroneal nerve only; $n = 2$, posterior tibial nerve and superficial peroneal nerve). The authors also concluded that the adduction and internal rotation position of the lower limb used during traction with a perineal post results in significant stress on the sciatic nerve and is one of the reasons for the documented findings. In addition, Martin et al speculated that the stress placed on affected nerves may be the reason for compromised adductor function postoperatively, which may negatively affect the rehabilitation process.

TABLE 4
Hip Arthroscopy Cases of Pudendal Nerve Injury

Study	Total Cases, n	Complications, n
Glick et al (1987) ¹⁶	60	4—pudendal neurapraxia
Schindler et al (1995) ³⁷	24	2—pudendal nerve dysesthesia
Funke and Munzinger (1996) ¹⁴	19	1—pudendal neurapraxia
Farjo et al (1999) ¹²	28	1—pudendal nerve palsy
Clarke et al (2003) ⁸	1054	5—neurapraxia
Kocher et al (2005) ²²	54	3—pudendal nerve palsy
Byrd and Jones (2009) ³	100	1—pudendal neuralgia
Gedouin et al (2010) ¹⁵	111	1—pudendal neuralgia
Souza et al (2010) ³⁹	194	5—pudendal nerve palsy
Byrd and Jones (2011) ⁴	100	3—pudendal neurapraxia
Nwachukwu et al (2011) ³⁰	218	2—pudendal nerve palsy
Pailhé et al (2013) ³¹	150	3—pudendal neuralgia
Polat et al (2013) ³⁴	42	2—pudendal neurapraxia
Park et al (2014) ³²	200	4—pudendal neurapraxia

TABLE 5
Hip Arthroscopy Cases of Reported
Perineal Soft Tissue Damage

Study	Total Cases, n	Complications, n
Funke and Munzinger (1996) ¹⁴	19	1—vulvar hematoma
Griffin and Villar (1999) ¹⁷	640	1—vaginal tear
Clarke et al (2003) ⁸	1054	1—vaginal tear
Gedouin et al (2010) ¹⁵	111	1—skin necrosis of labium
Souza et al (2010) ³⁹	194	1—vulva edema, 1—skin necrosis of scrotum

Telleria et al⁴⁰ also used intraoperative nerve monitoring of the tibial and common peroneal nerves during hip arthroscopy and reported 35 “nerve events” (50% reduction in amplitude of somatosensory evoked potentials or transcranial motor evoked potentials or a 10% increase in the latency of somatosensory evoked potentials) during 60 procedures (58% rate). Only 4 patients demonstrated clinical nerve symptoms postoperatively. The authors also monitored traction force throughout the procedure and correlated this with nerve dysfunction. They calculated that the odds of a nerve event increased by 4% for every 1-lb increase in traction weight. Finally, the authors observed that traction time did not increase the probability of a nerve event and that age and sex were not significant risk factors.

In addition to comparing prevalence of complications between the present study and those cited, it is important to compare traction forces. Telleria et al⁴⁰ reported a mean peak distraction force of 79.3 ± 17.9 lb while using a perineal post in the lateral position. In contrast, when using the postless technique, we found a mean peak distraction force of 89.6 ± 28.1 lb. Once the hip was adequately distracted, the mean distraction force (at 20 minutes) decreased to 67.6 ± 24.2 lb, which is lower than the peak distraction forces reported by Telleria et al. This finding

indicates that during arthroscopic hip procedures using a post-free method facilitated by the Trendelenburg position require traction forces similar to those necessary with a traction post. However, we should recognize a possible bias with this comparison. There is some variability in the amount of traction and resultant joint space utilized by surgeons to safely enter the hip joint, and no current standardization is available.

Soft tissue injuries related to the use of a perineal post have also been reported in the literature. In 1974, Aboulker et al¹ reported on 3 cases of perineal injuries. Peterson³³ reported on 4 cases of genitoperineal injury. Callanan et al⁵ reported a case of massive perineal slough involving the entire perineal skin, from the base of the scrotum to the anus. Hammit et al¹⁹ also reported a severe case of massive perineal slough. Choudhuri et al⁷ described a case of significant vulval hematoma and dysesthesia, and Coelho et al⁹ reported 6 cases of perineal skin necrosis. This is another type of post-related complication unseen in the current study.

This study is not the first to attempt to eliminate the use of a perineal post during hip arthroscopy. Flecher et al¹³ performed external fixation with threaded pins inserted in the femoral diaphysis and the roof of the acetabulum. Using this setup, the authors reported no neurologic complications in a series of 23 patients undergoing hip arthroscopy. However, these pins come with their own potential complications, including iatrogenic fracture, infection, and increased postoperative pain. Merrell et al²⁹ attempted hip distraction with the use of a deflated beanbag extending from the torso to the iliac crest. However, the authors still used a perineal post during initial positioning and during induction of general anesthesia, and so this technique only reduces the amount of time during which the perineal post is used rather than eliminating its use completely. Mei-Dan et al²⁸ described the use of a perineal post against the medial thigh, 10 cm distal to the perineum. The authors reported no groin- or perineal-related complications in >2000 hip arthroscopies. However, the use of a perineal post against the medial thigh presents new potential complications, such as obturator neurapraxias.

TABLE 6
Advantages of Hip Arthroscopy Distraction
Without a Perineal Post

1. Ability to use anteroposterior and true lateral fluoroscopy views when establishing portals or during cam lesion work. This enables safer, faster, and more reproducible work, which reduces the learning curve for inexperienced surgeons.
2. Ability to work with and without traction (central and peripheral compartments) during surgery without needing to move a post out of the way and then put it back. This is very helpful when cam resection is performed while the assistant prepares the graft for labral reconstruction.
3. Can position the leg in neutral position or slight abduction during traction, which relieves pressure from the sciatic nerve (adduction places more stress on the nerve). A perineal post forces femoral adduction.
4. Can work under traction for as long as necessary without needing to worry about groin/post-related complications.
5. Improved blood return to heart and brain perfusion.
6. Easier control of (low) blood pressure, which in turn enables the use of lower pump pressures and results in less tissue swelling.
7. No groin soft tissue- or nerve-related complications.

Most patients undergoing hip arthroscopy are young, athletic, and sexually active. Furthermore, hip arthroscopy is an elective procedure. Therefore, perineal nerve- and soft tissue-related complications should be considered unacceptable in this population undergoing this procedure. With the use of a perineal post, the largest barrier for new hip arthroscopists and the most significant concern for experienced surgeons is not the procedure itself but rather the potential complications that may arise based on patient positioning.

In addition to eliminating nerve- and soft tissue-related complications, the use of the postless technique for hip arthroscopy offers numerous advantages (Table 6). In particular, for new hip arthroscopists who need more time to enter the joint and work in the central compartment, the post-free technique minimizes concerns of complications that may become evident postoperatively. Therefore, this technique allows surgeons to focus on the procedure itself rather than the complications that may occur with the use of a traction post. Another advantage, which allows the surgeon to enter the joint safely and reproducibly, is the ability to use anteroposterior and true lateral fluoroscopy views when positioning the first needle while establishing the first portal. Another advantage possibly affects the anesthetic and surgical fronts, and this is improved blood return to the heart and brain perfusion attributed to the inclined position, which may make it easier to control and maintain a lower blood pressure, thereby enabling the use of lower pump pressure. Finally, the ability to perform bilateral hip arthroscopy under the same anesthetic without accumulated groin-related stress and increased groin-related complications enables faster recovery for patients with bilateral disease.²⁵

Traditionally, the lateralized perineal post was also advocated in that it permitted a laterally directed force vector on the upper femur, thereby improving visualization of the cotyloid fossa, ligamentum teres, and medial aspect of the femoral head. The present cohort of 1000 hips underwent a variety of procedures, including ligamentum teres

debridement and reconstruction, acetabular and medial femoral head microfracture, and removal of loose bodies from the posteromedial joint. The technique described herein allowed safe access to the medial or posterior joint, reinforcing that a lateralized perineal post is not required to access the medial aspect of the central compartment.

The strengths of this study include the prospective study design and the large sample size. Also, for many of the surgical procedures included in this study, access and interportal capsulotomy were performed by a hip preservation fellow, often requiring longer operative times when compared with those of an experienced surgeon. Nevertheless, although this resulted in longer traction time, no complications or side effects were appreciated, validating this technique and the reported results for inexperienced surgeons. The limitations of this study should be noted. In particular, this was a single-surgeon case series, and there is a learning curve involved for surgeons as they begin to use the postless traction technique. However, this technique is easily taught and reproducible, and all hip preservation fellows trained in this technique continued its use in their respective practices. Another limitation of this study is that the Trendelenburg angle was not uniform for all patients. Rather, the appropriate angle was estimated according to the surgeon's experience. Thus, some associations found in this study, particularly that between patient weight and initial distraction force, should be evaluated accordingly.

CONCLUSION

Compression neurapraxias and soft tissue damage to the perineum have been well documented as complications directly related to the use of a perineal post during hip arthroscopy. This study is the first to report the use of a new technique for patient positioning during hip arthroscopy without the need for a perineal post at any point during positioning. No complications related to the traction technique were reported in 1000 prospectively followed hip arthroscopies. This procedure limits the complications of intraoperative pudendal nerve palsy and soft tissue damage to the groin and allows safe, adequate, reproducible access to the hip joint.

A Video Supplement for this article is available online.

REFERENCES

1. Aboulker P, Benassayag E, Steg A. Injuries of the perineum caused by traction on the orthopedic table with pelvi-support (3 cases) [in French]. *Rev Chir Orthop Reparatrice Appar Mot.* 1974;60(2):165-168.
2. Byrd JW. Hip arthroscopy utilizing the supine position. *Arthroscopy.* 1994;10(3):275-280.
3. Byrd JW, Jones KS. Arthroscopic management of femoroacetabular impingement. *Instr Course Lect.* 2009;58:231-239.
4. Byrd JW, Jones KS. Arthroscopic management of femoroacetabular impingement: minimum 2-year follow-up. *Arthroscopy.* 2011;27(10):1379-1388.
5. Callanan I, Choudhry V, Smith H. Perineal sloughing as a result of pressure necrosis from the traction post during prolonged bilateral femoral nailing. *Injury.* 1994;25(7):472.

6. Chan PT, Schondorf R, Brock GB. Erectile dysfunction induced by orthopaedic trauma managed with a fracture table: a case report and review of the literature. *J Trauma*. 1999;47(1):183-185.
7. Choudhuri AH, Sharma H, Dharmani P, Goyal N. Vulval injury due to perineal post on fracture table: concern for anaesthesiologist. *Int J Anesth*. 2007;11(2):1-4.
8. Clarke MT, Arora A, Villar RN. Hip arthroscopy: complications in 1054 cases. *Clin Orthop Relat Res*. 2003;406:84-88.
9. Coelho RF, Gomes CM, Sakaki MH, et al. Genitoperineal injuries associated with the use of an orthopedic table with a perineal post-traction. *J Trauma*. 2008;65(4):820-823.
10. Dienst M, Seil R, Göttsche S, et al. Effects of traction, distention, and joint position on distraction of the hip joint: an experimental study in cadavers. *Arthroscopy*. 2002;18(8):865-871.
11. Dippmann C, Thorborg K, Kraemer O, Winge S, Hölmich P. Symptoms of nerve dysfunction after hip arthroscopy: an under-reported complication? *Arthroscopy*. 2014;30(2):202-207.
12. Farjo LA, Glick JM, Sampson TG. Hip arthroscopy for acetabular labral tears. *Arthroscopy*. 1999;15(2):132-137.
13. Flecher X, Dumas J, Argenson JN. Is a hip distractor useful in the arthroscopic treatment of femoroacetabular impingement? *Orthop Traumatol Surg Res*. 2011;97(4):381-388.
14. Funke EL, Munzinger U. Complications in hip arthroscopy. *Arthroscopy*. 1996;12(2):156-159.
15. Gedouin JE, May O, Bonin N, et al. Assessment of arthroscopic management of femoroacetabular impingement: a prospective multicenter study. *Orthop Traumatol Surg Res*. 2010;96(8):S59-S67.
16. Glick JM, Sampson TG, Gordon RB, Behr JT, Schmidt E. Hip arthroscopy by the lateral approach. *Arthroscopy*. 1987;3(1):4-12.
17. Griffin DR, Villar RN. Complications of arthroscopy of the hip. *J Bone Joint Surg Br*. 1999;81(4):604-606.
18. Gupta A, Redmond JM, Hammarstedt JE, Schwindel L, Domb BG. Safety measures in hip arthroscopy and their efficacy in minimizing complications: a systematic review of the evidence. *Arthroscopy*. 2014;30(10):1342-1348.
19. Hammit MD, Cole PA, Kregor PJ. Massive perineal wound slough after treatment of complex pelvic and acetabular fractures using a traction table. *J Orthop Trauma*. 2002;16(8):601-605.
20. Harris JD, McCormick FM, Abrams GD, et al. Complications and reoperations during and after hip arthroscopy: a systematic review of 92 studies and more than 6,000 patients. *Arthroscopy*. 2013;29(3):589-595.
21. Kocaoğlu H, Başarir K, Akmeşe R, et al. The effect of traction force and hip abduction angle on pudendal nerve compression in hip arthroscopy: a cadaveric model. *Arthroscopy*. 2015;31(10):1974-1980.e6.
22. Kocher MS, Kim YJ, Millis MB. Hip arthroscopy in children and adolescents. *J Pediatr Orthop*. 2005;25(5):680-686.
23. Kraeutler MJ, Garabekyan T, Pascual-Garrido C, Mei-Dan O. Hip instability: a review of hip dysplasia and other contributing factors. *Muscles Ligaments Tendons J*. 2016;6(3):343-353.
24. Martin HD, Palmer IJ, Champlin K, Kaiser B, Kelly B, Leunig M. Physiological changes as a result of hip arthroscopy performed with traction. *Arthroscopy*. 2012;28(10):1365-1372.
25. McConkey MO, Chadayammuri V, Garabekyan T, Mayer SW, Kraeutler MJ, Mei-Dan O. Simultaneous bilateral hip arthroscopy in adolescent athletes with symptomatic femoroacetabular impingement [published online April 3, 2017]. *J Pediatr Orthop*. doi: 10.1097/BPO.0000000000000987.
26. McConkey MO, Moreira B, Mei-Dan O. Arthroscopic hip labral reconstruction and augmentation using knotless anchors. *Arthrosc Tech*. 2015;4(6):e701-e705.
27. Mei-Dan O, McConkey MO, Petersen B, McCarty E, Moreira B, Young DA. The anterior approach for a non-image-guided intra-articular hip injection. *Arthroscopy*. 2013;29(6):1025-1033.
28. Mei-Dan O, McConkey MO, Young DA. Hip arthroscopy distraction without the use of a perineal post: prospective study. *Orthopedics*. 2013;36(1):e1-e5.
29. Merrell G, Medvecky M, Daigneault J, Jokl P. Hip arthroscopy without a perineal post: a safer technique for hip distraction. *Arthroscopy*. 2007;23(1):107.e1-e3.
30. Nwachukwu BU, McFeely ED, Nasreddine AY, Krcik JA, Frank J, Kocher MS. Complications of hip arthroscopy in children and adolescents. *J Pediatr Orthop*. 2011;31(3):227-231.
31. Pailhé R, Chiron P, Reina N, Cavaignac E, Lafontan V, Laffosse JM. Pudendal nerve neuralgia after hip arthroscopy: retrospective study and literature review. *Orthop Traumatol Surg Res*. 2013;99(7):785-790.
32. Park MS, Yoon SJ, Kim YJ, Chung WC. Hip arthroscopy for femoroacetabular impingement: the changing nature and severity of associated complications over time. *Arthroscopy*. 2014;30(8):957-963.
33. Peterson NE. Genitoperineal injury induced by orthopedic fracture table. *J Urol*. 1985;134(4):760-761.
34. Polat G, Dikmen G, Erdil M, Aşık M. Arthroscopic treatment of femoroacetabular impingement: early outcomes. *Acta Orthop Traumatol Turc*. 2013;47(5):311-317.
35. Polyzois I, Tsitskaris K, Oussedik S. Pudendal nerve palsy in trauma and elective orthopaedic surgery. *Injury*. 2013;44(12):1721-1724.
36. Rudge P. Tourniquet paralysis with prolonged conduction block: an electro-physiological study. *J Bone Joint Surg Br*. 1974;56(4):716-720.
37. Schindler A, Lechevallier JJ, Rao NS, Bowen JR. Diagnostic and therapeutic arthroscopy of the hip in children and adolescents: evaluation of results. *J Pediatr Orthop*. 1995;15(3):317-321.
38. Sing DC, Feeley BT, Tay B, Vail TP, Zhang AL. Age-related trends in hip arthroscopy: a large cross-sectional analysis. *Arthroscopy*. 2015;31(12):2307-2313.e2.
39. Souza BG, Dani WS, Honda EK, et al. Do complications in hip arthroscopy change with experience? *Arthroscopy*. 2010;26(8):1053-1057.
40. Telleria JJ, Safran MR, Harris AH, Gardi JN, Glick JM. Risk of sciatic nerve traction injury during hip arthroscopy—is it the amount or duration? An intraoperative nerve monitoring study. *J Bone Joint Surg Am*. 2012;94(22):2025-2032.